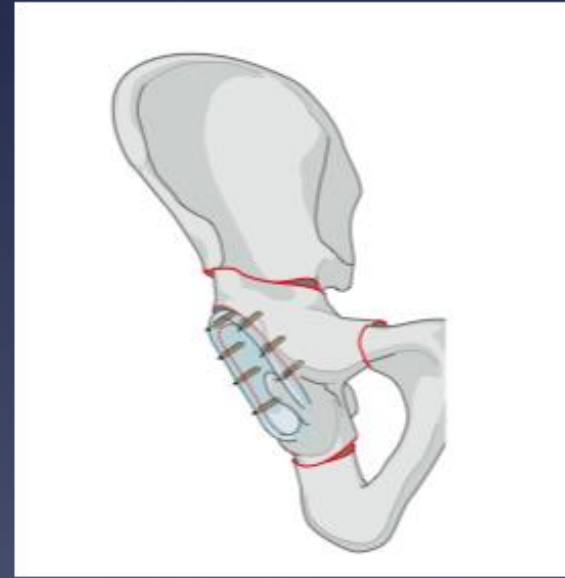
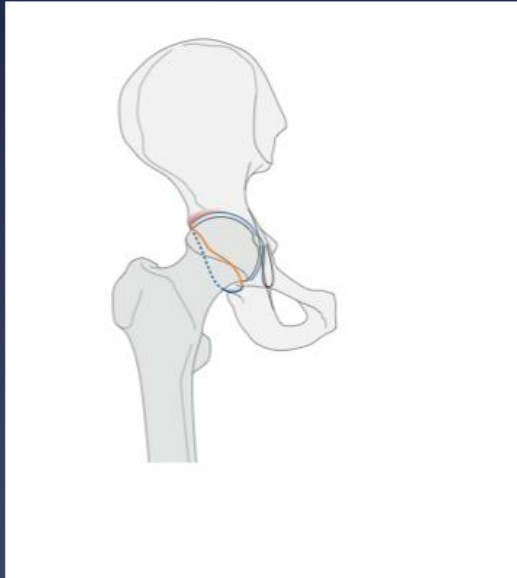


# Open Hip Preservation Surgery



**Thomas W. Huff, MD, FAAOS**

Associate Professor of Orthopaedics and Rehabilitation

Fellowship Director, Adult Reconstruction and Hip Preservation Surgery

Oregon Health & Science University

Portland, Oregon

[hufft@ohsu.edu](mailto:hufft@ohsu.edu)

# Disclosures: none relevant to this topic

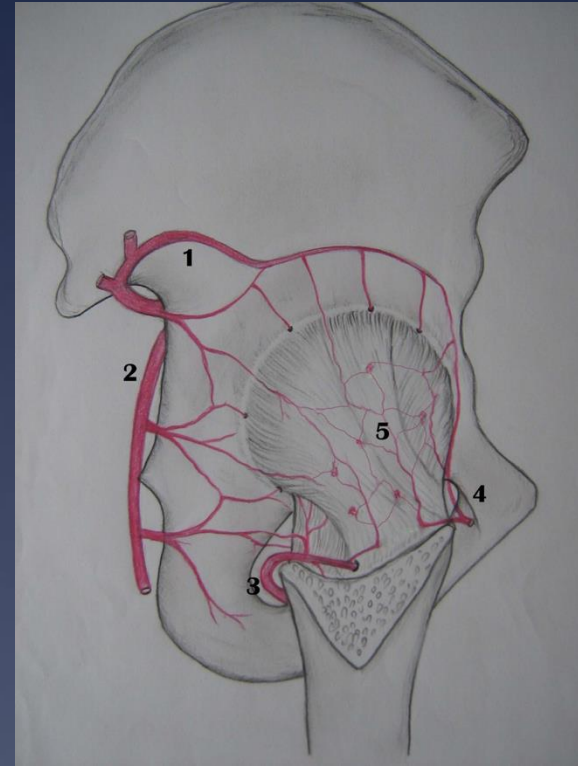
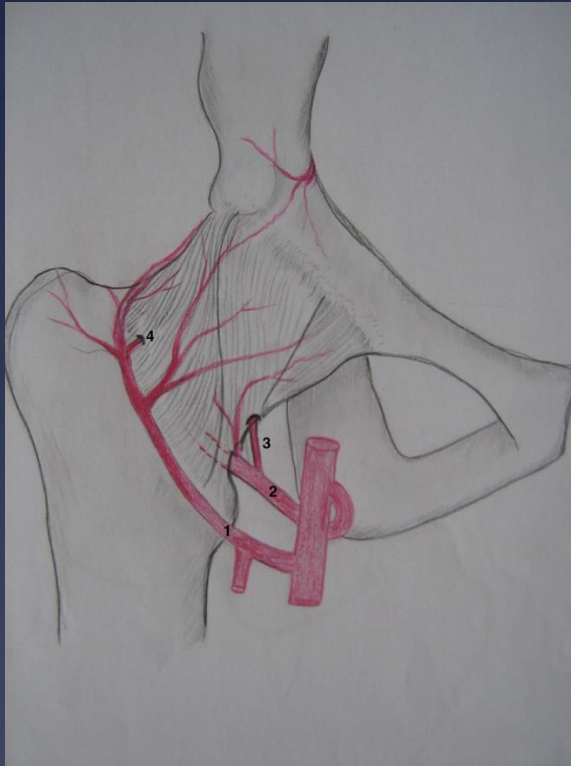
- \* Fellowship Support:
  - AAHKS
  - Smith & Nephew
- \* Research support and consulting:
  - Smith & Nephew
  - Zimmer Biomet
  - JointMedica
- \* Consultant:
  - Enovis
  - Signature Orthopaedics
- \* Oregon Surgical Institute, founding partner

# Overview

- \* Surgical Dislocation of the Hip
  - \* Controlled exposure of the femoral head and acetabulum while preserving the blood supply
  - \* Ganz, et al. JBJS-Br 2001
- \* Retinacular Soft Tissue Flap
  - \* Intra-articular osteotomies of the femoral neck
  - \* Sub-capital reorientation in SCFE
  - \* Femoral head reduction



# Vascular Anatomy of the Adult Hip

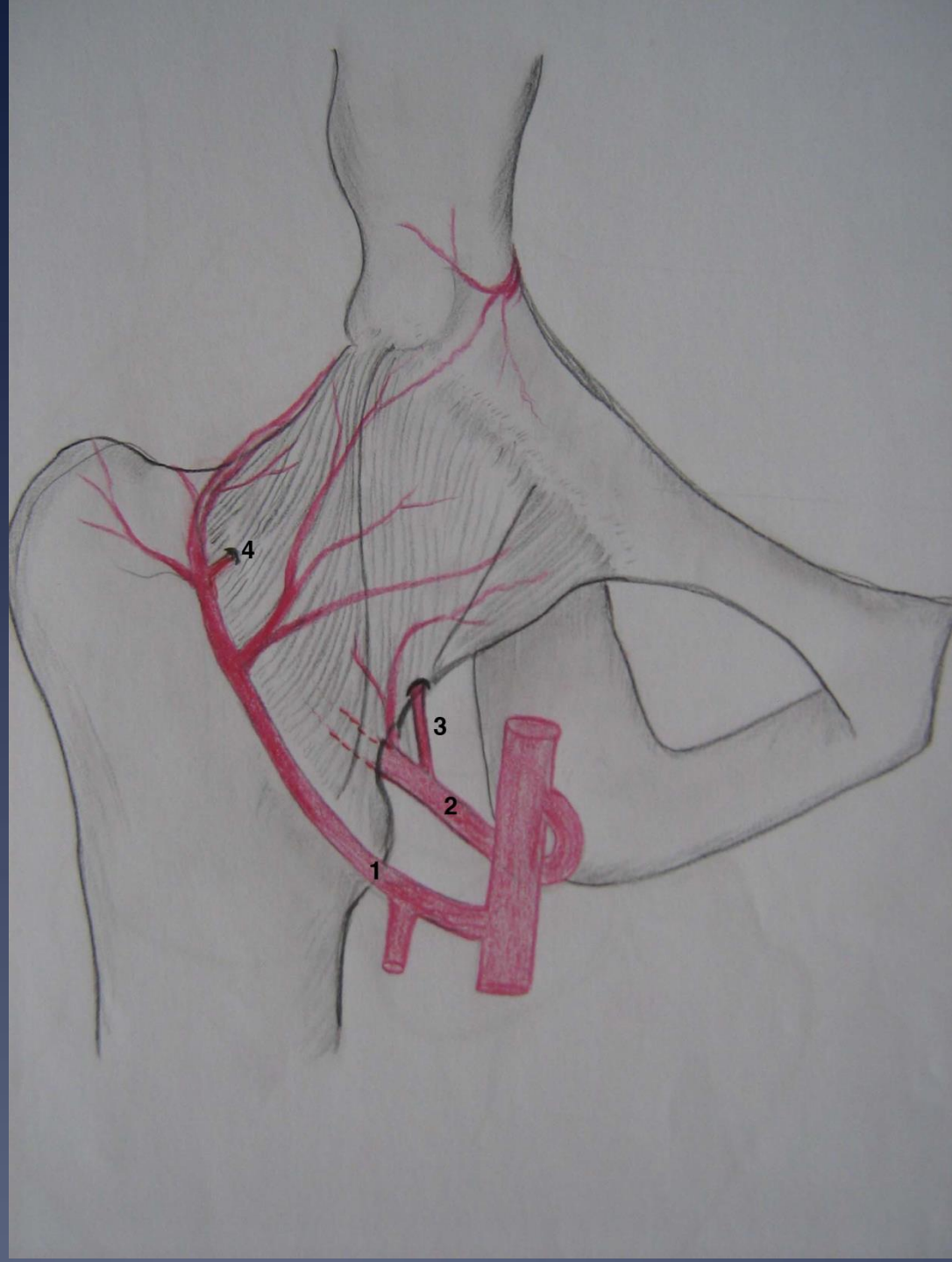


## **Anatomy of the medial femoral circumflex artery and its surgical implications**

Emanuel Gautier, Katharine Ganz, Nathalie Krügel, Thomas Gill, Reinhold Ganz

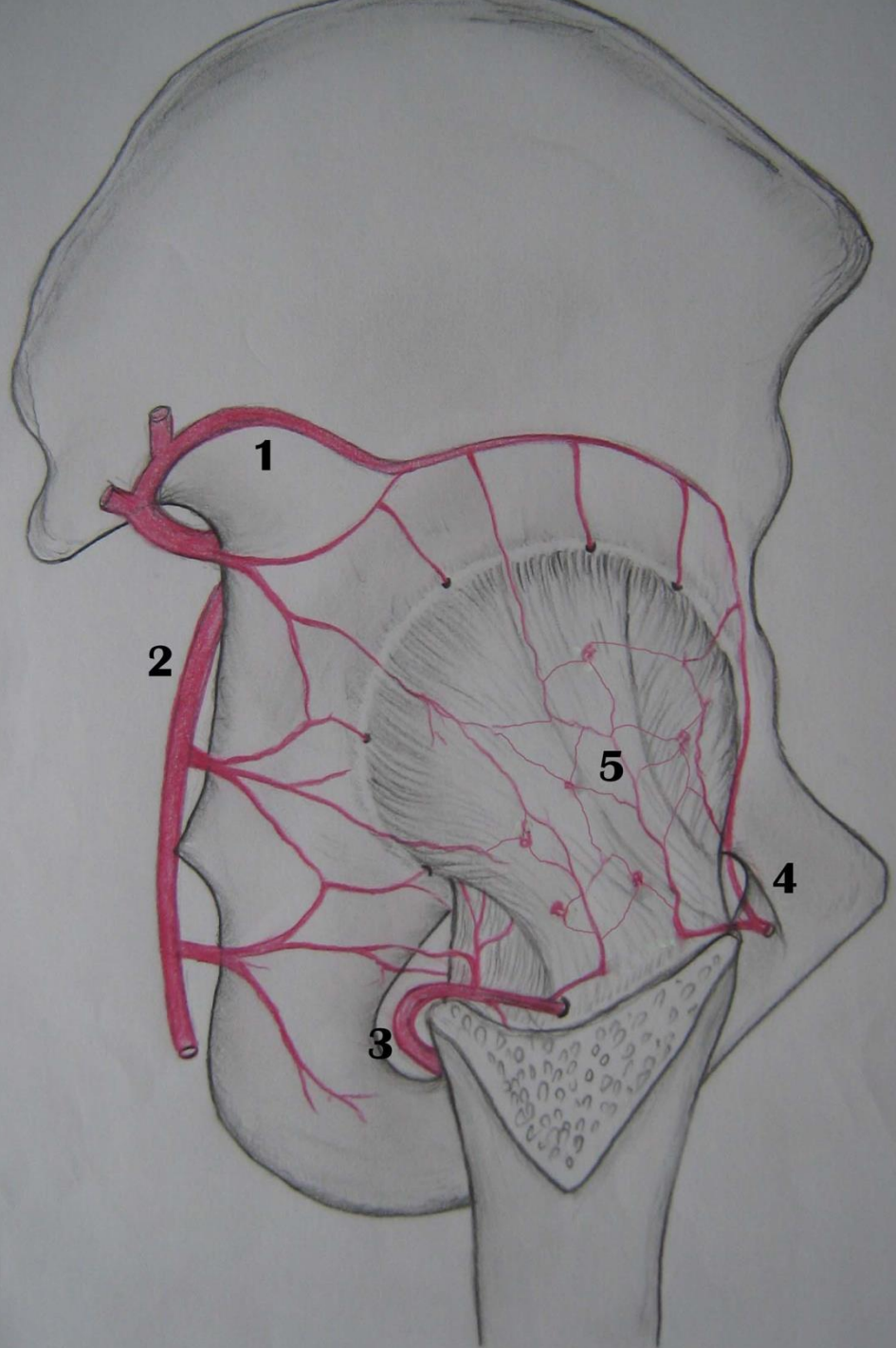
*J Bone Joint Surg [Br] 2000;82-B:679-83.*

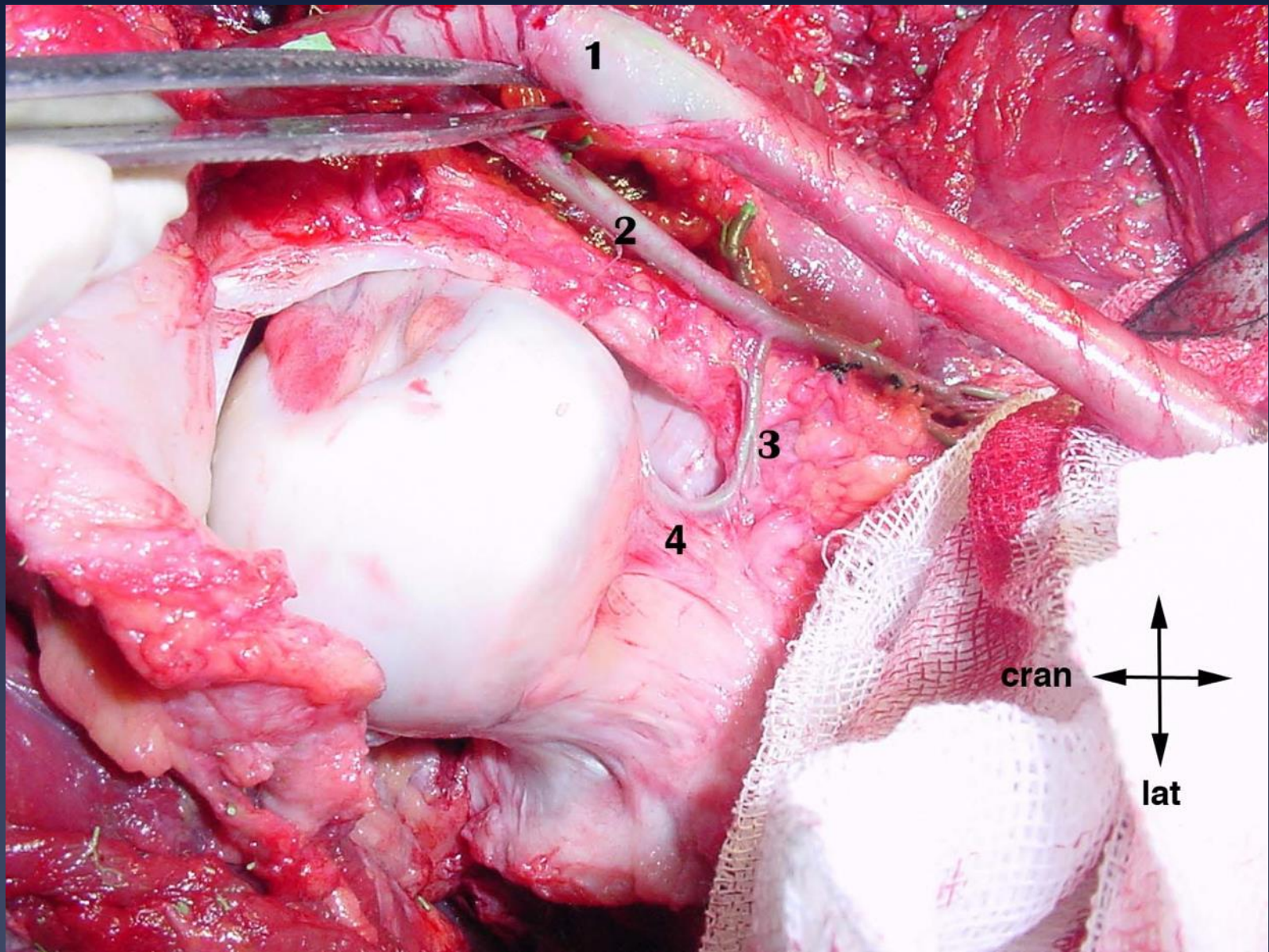
- 1 LFCA
- 2 MFCA
- 3 Inferomedial  
retinacular  
branch
- 4 Variable LFCA  
retinacular  
branch





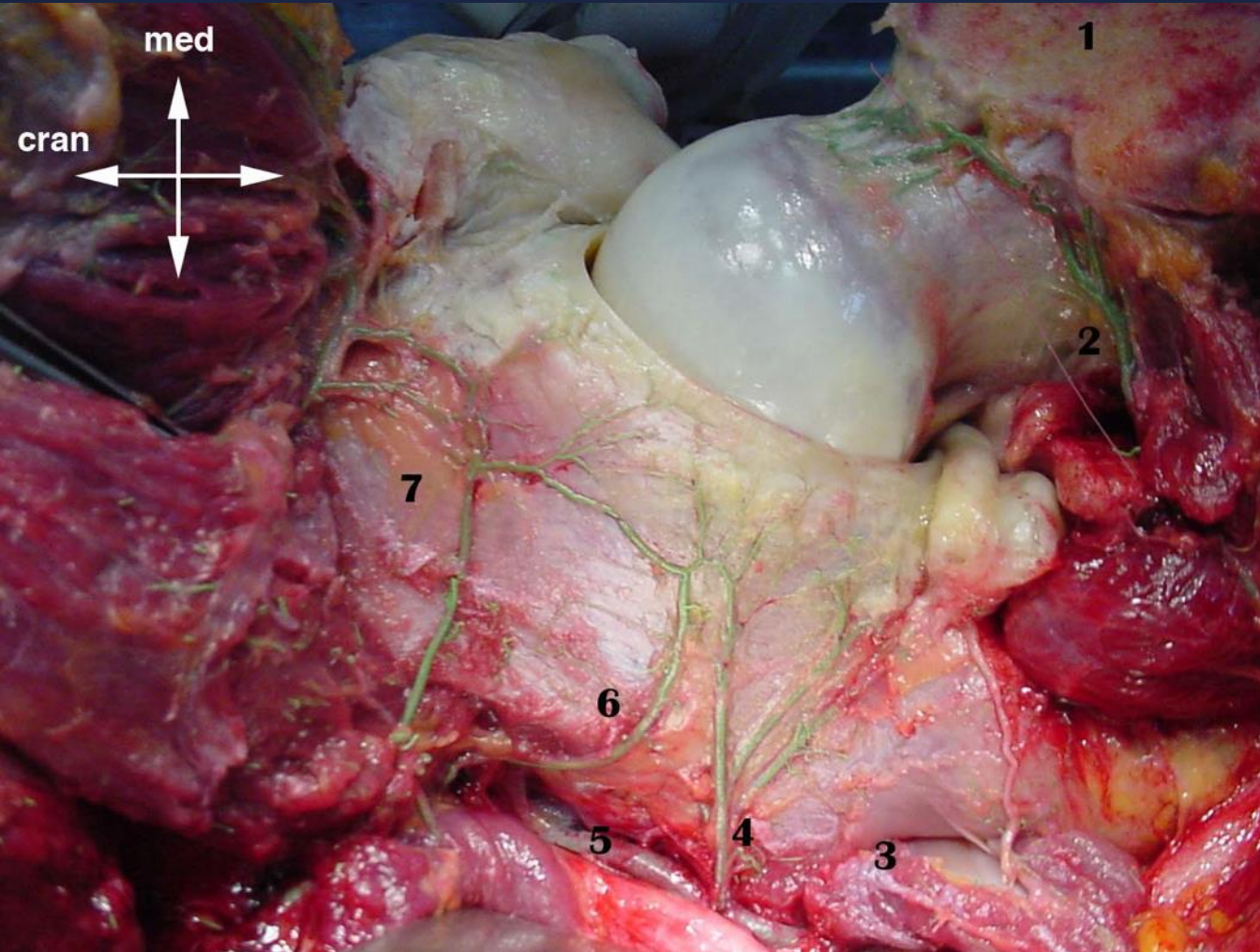
- 1 Superior Gluteal Artery
- 2 Inferior Gluteal Artery
- 3 Medial Femoral Circumflex Artery
- 4 Lateral Femoral Circumflex Artery
- 5 Capsular Blood Supply





1. Femoral Artery
2. MFCA
3. Inferomedial Retinacular Branch



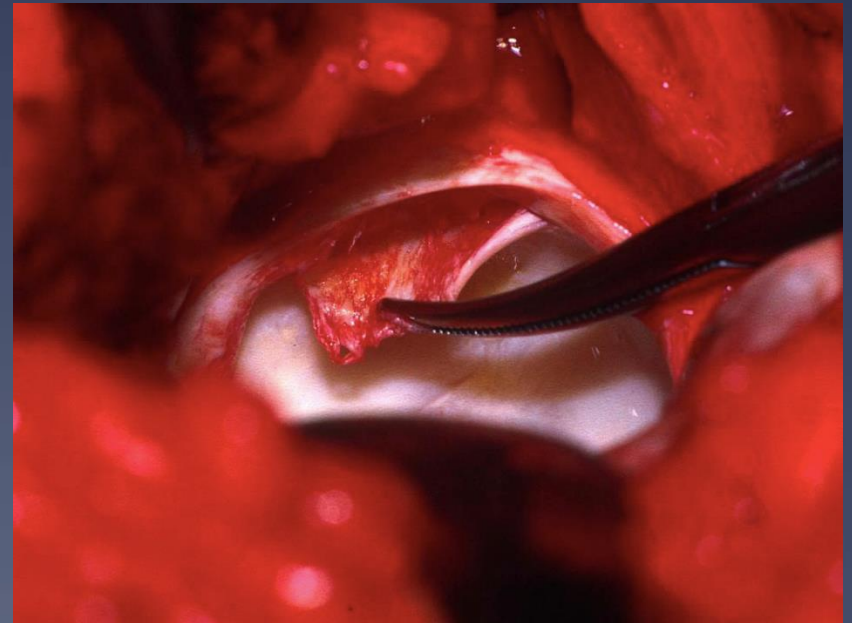
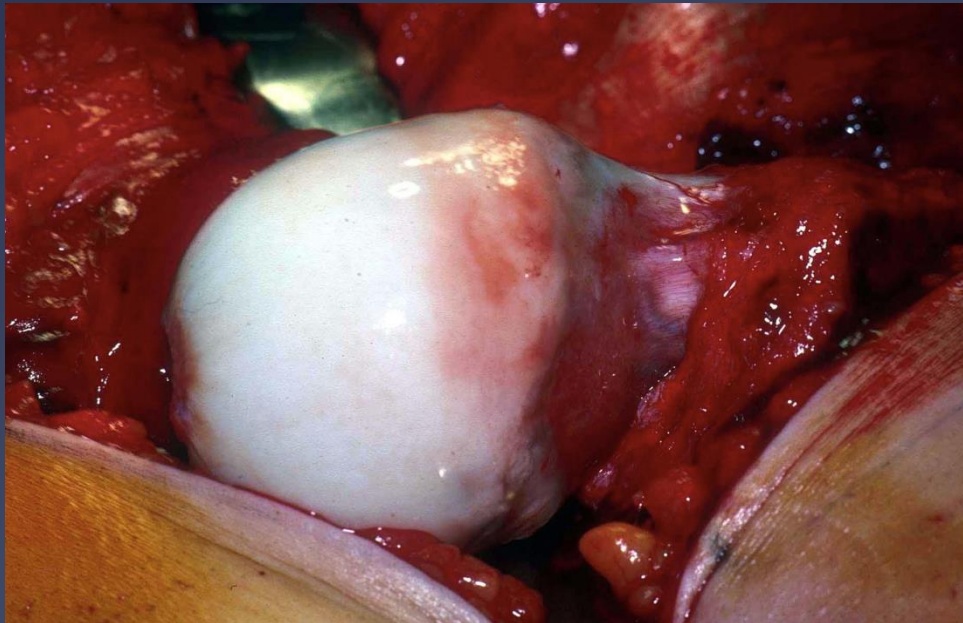
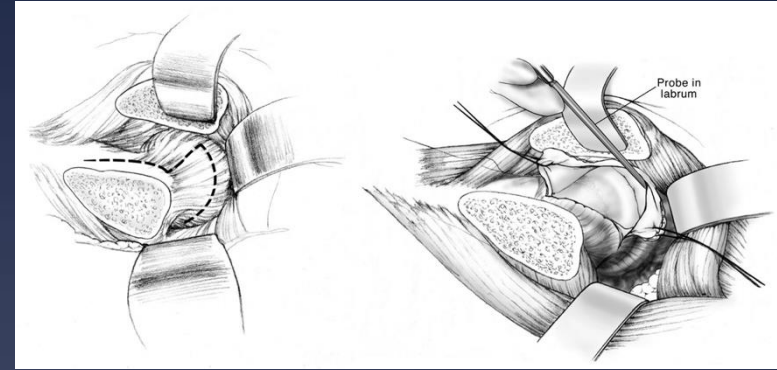


- 1 Greater trochanter
- 2 MFCA deep branch
- 3 Lesser sciatic notch
- 4 Acetabular branch of IGA
- 5 IGA
- 6 Acetabular branch of SGA
- 7 Supra-acetabular branch of SGA

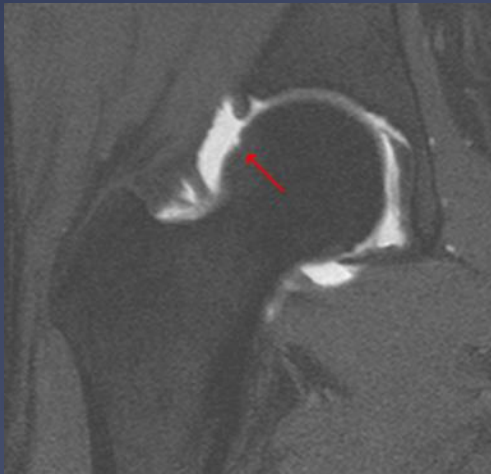
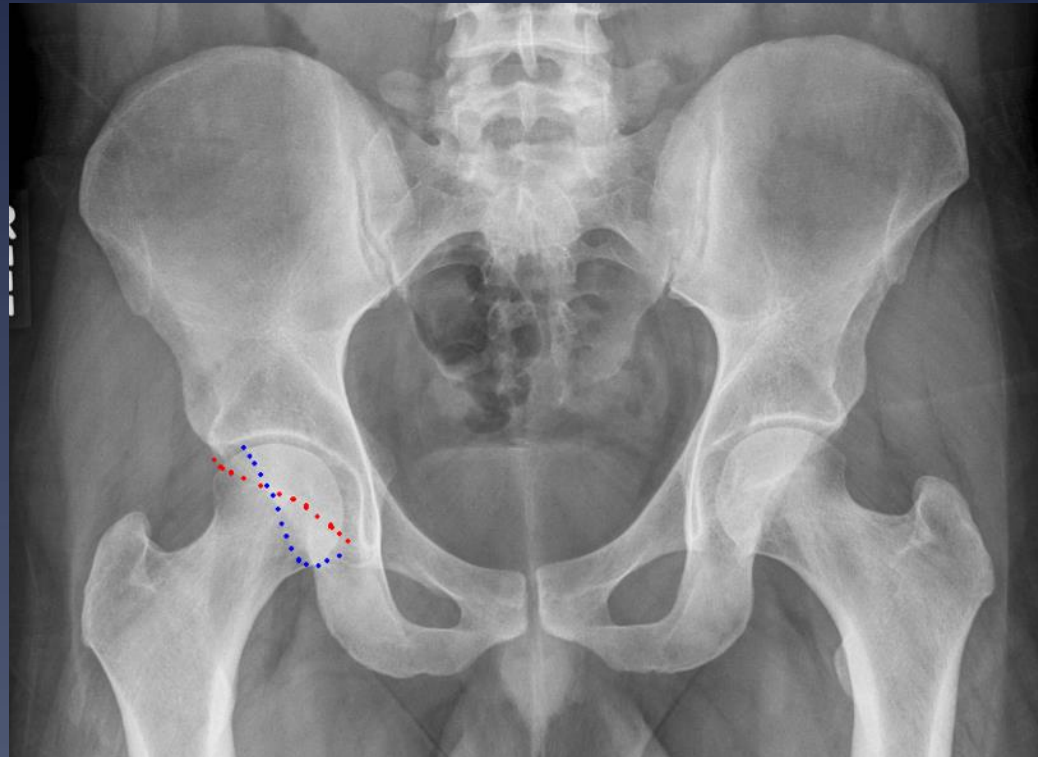
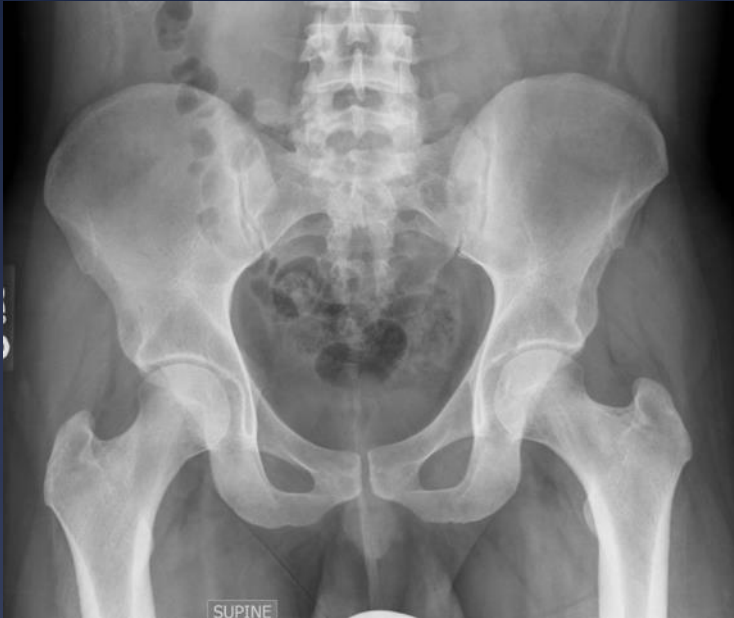

# Surgical Dislocation

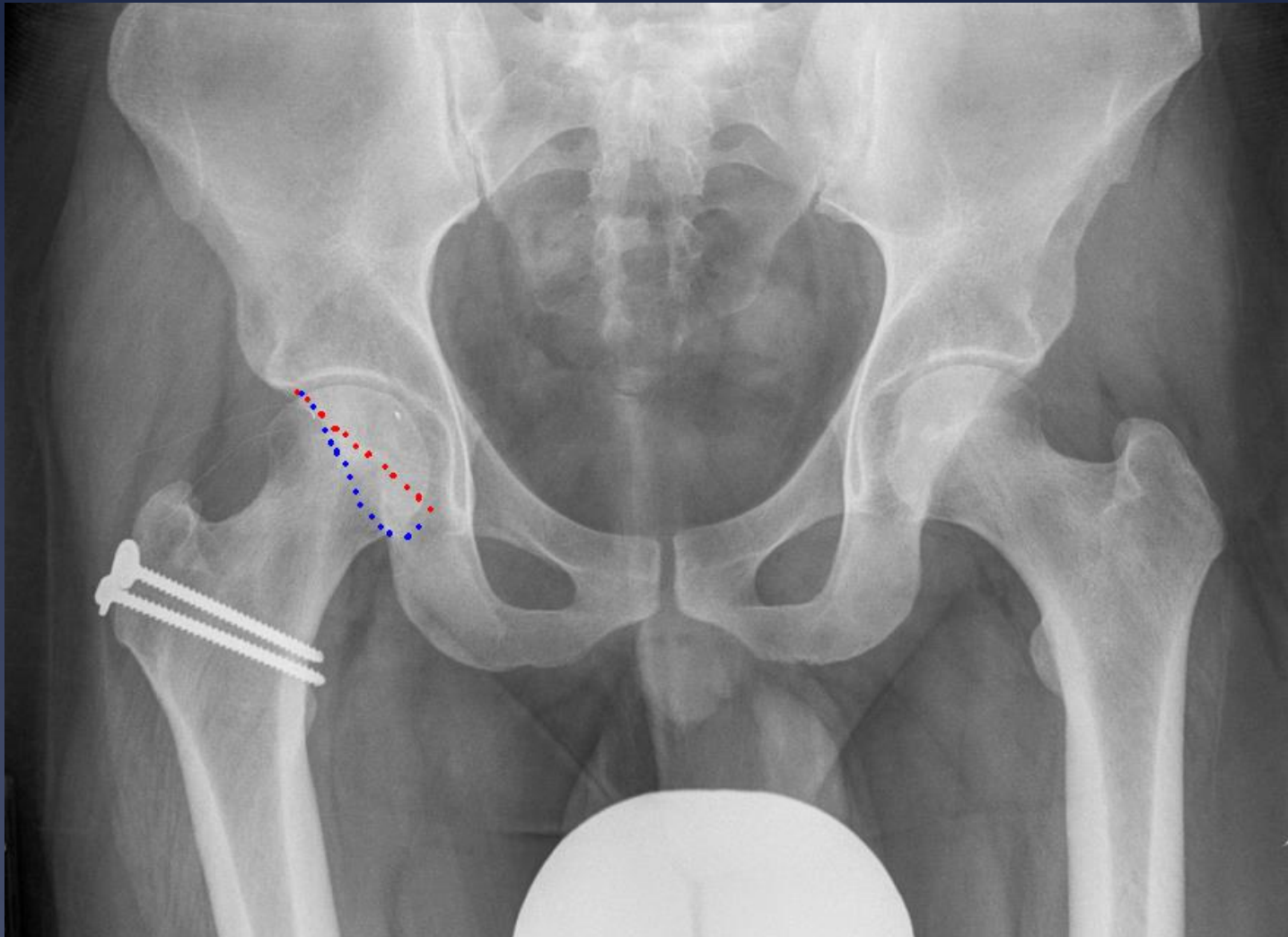
- \* Safe, wide exposure of the entire femoral head and acetabulum
- \* Treatment of FAI
- \* Intra-articular fractures
- \* Intra-articular tumors, loose bodies



# Cranial Retroversion: Pincer Impingement



s/p SDH, rim trimming, and labral  
refixation



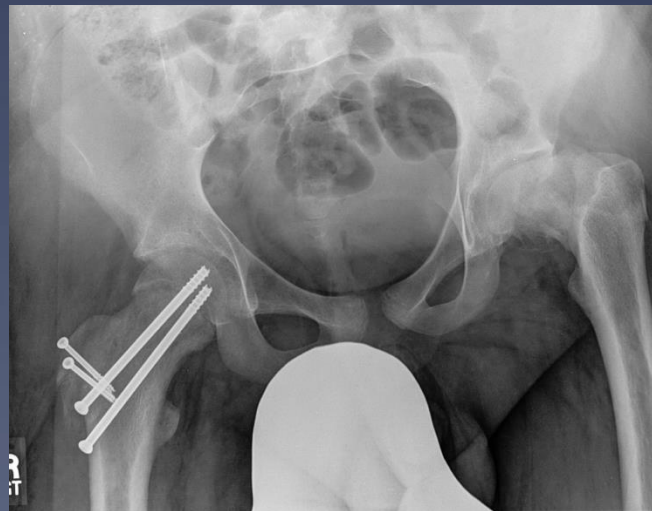
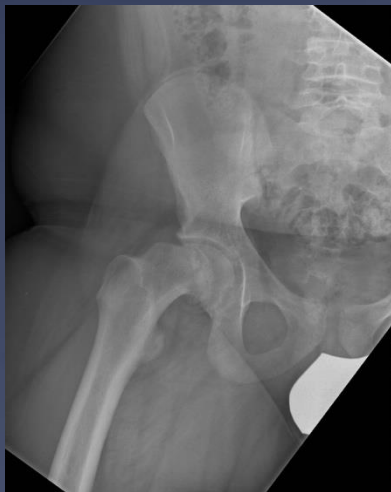

# Outcomes of Open FAI Treatment

- \* Joint preservation ~90% at 10 years; AVN < 1%
- \* Gold standard for treatment of complex intra-articular pathology
- \* Only option for intra-articular osteotomy

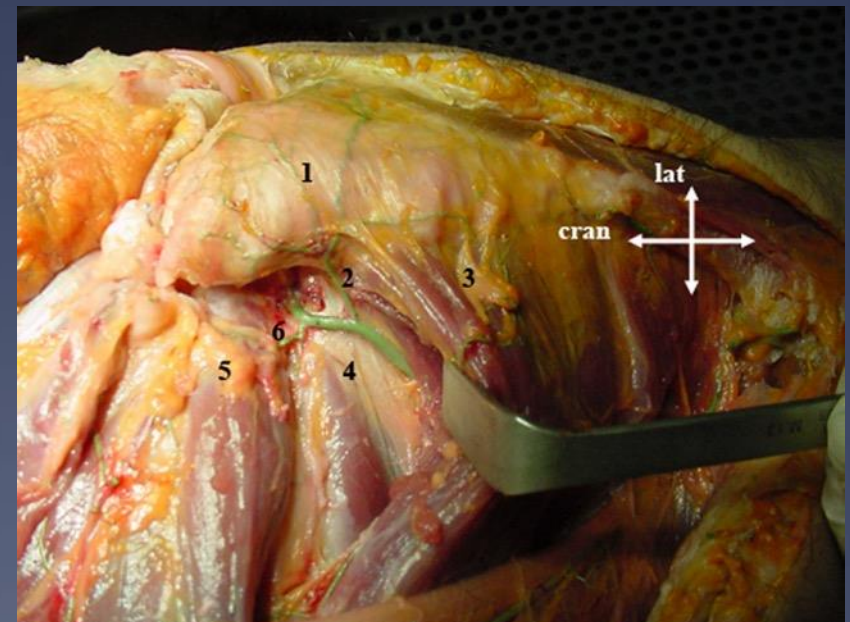
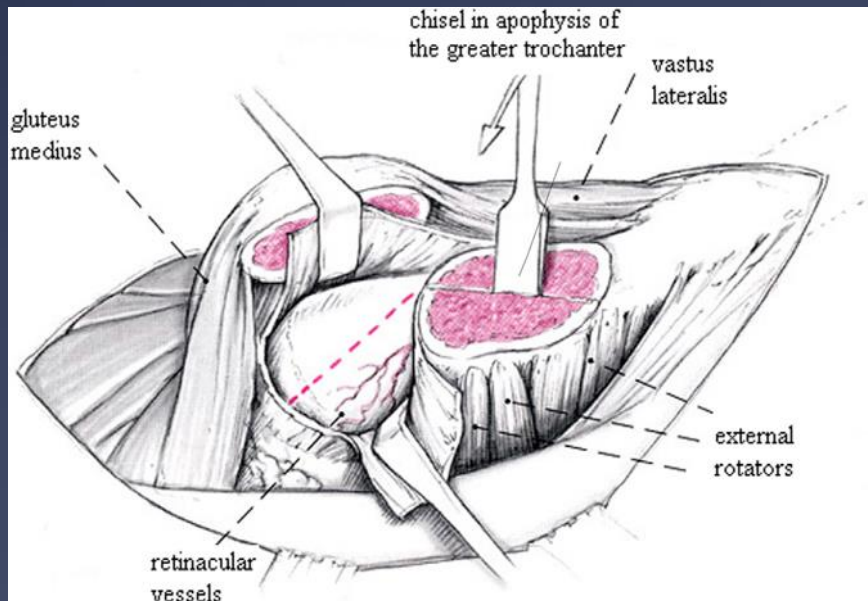
# Intra-articular Osteotomy

- \* Mobilization of the vessels that supply the femoral head in a subperiosteal flap
- \* Indications: SCFE, Perthes, post-traumatic varus/valgus neck deformity



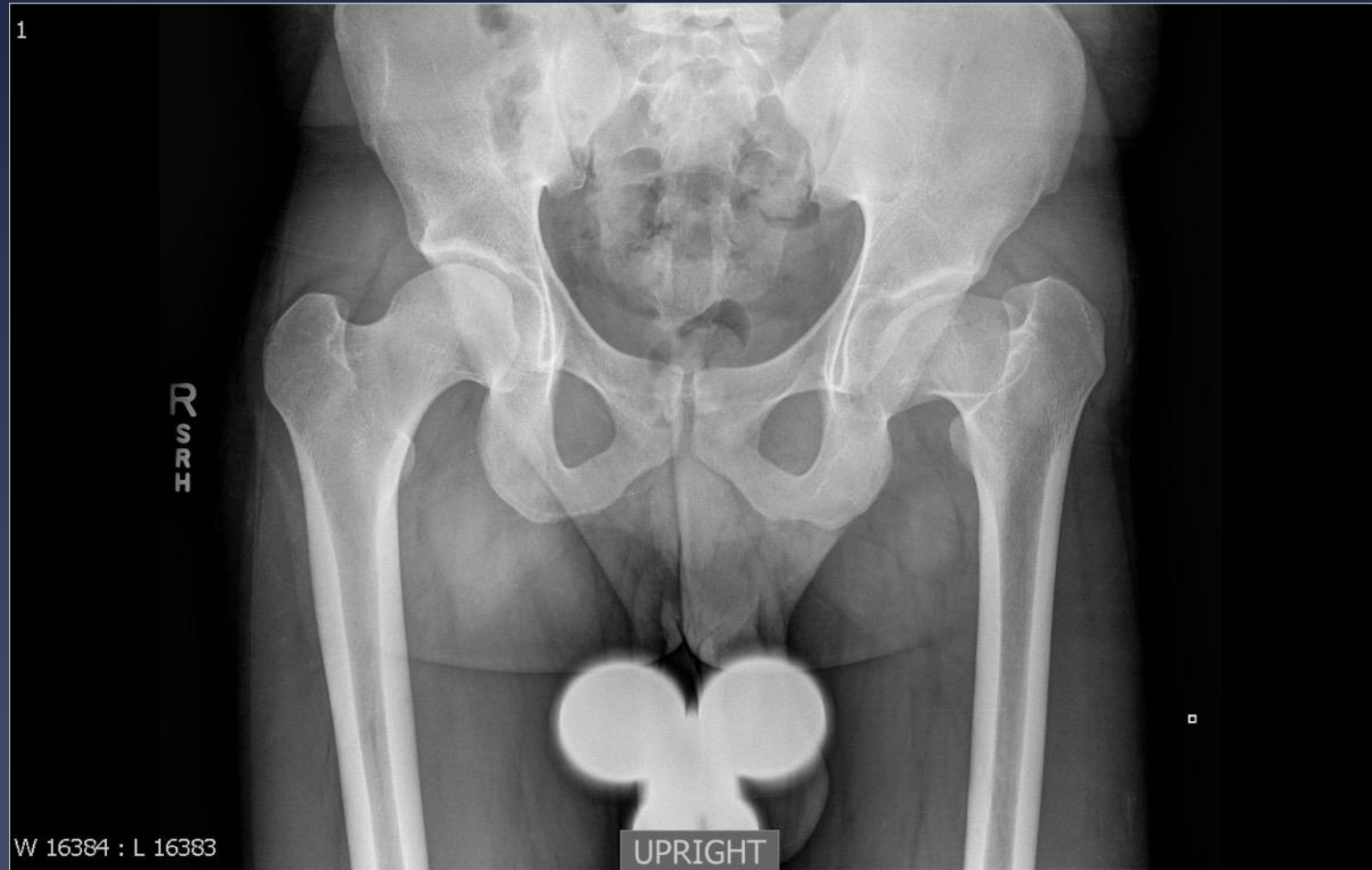# Technique

- \* Ganz R, Huff TW, Leunig M. **Extended retinacular soft-tissue flap for intra-articular hip surgery: surgical technique, indications, and results of application.** Orthopaedics Department, Inselspital, University of Bern, Bern, Switzerland. Instr Course Lect. 2009;58:241-55

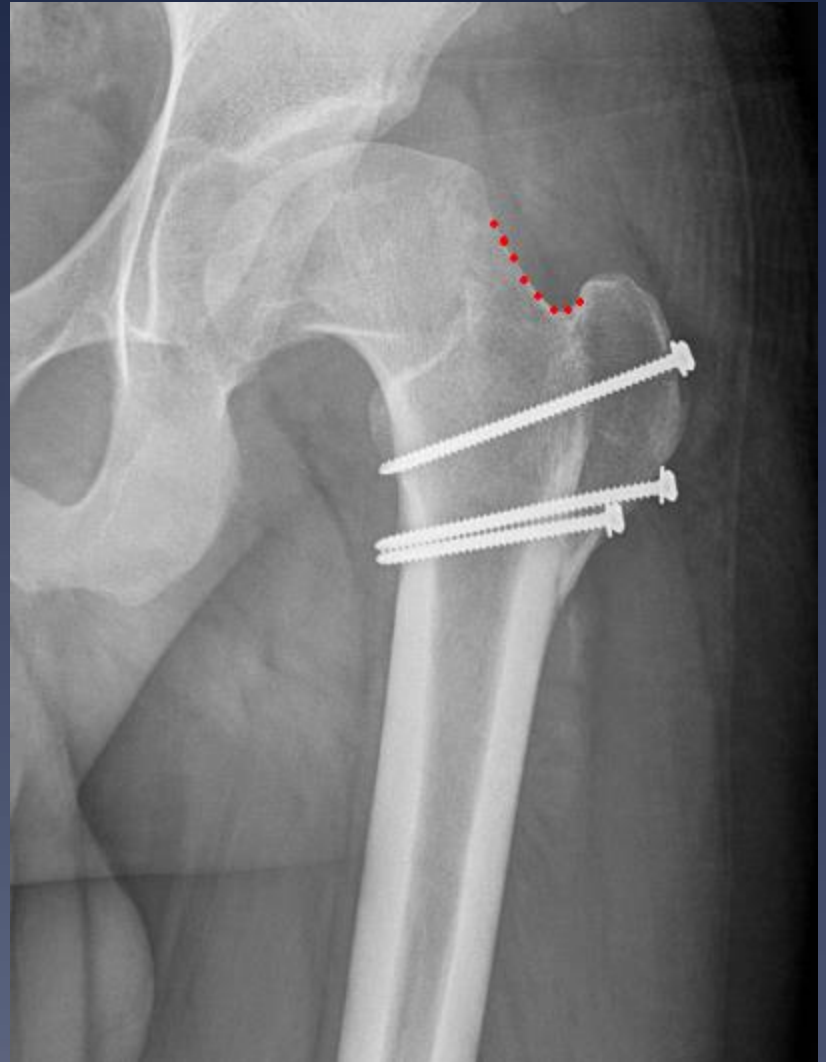
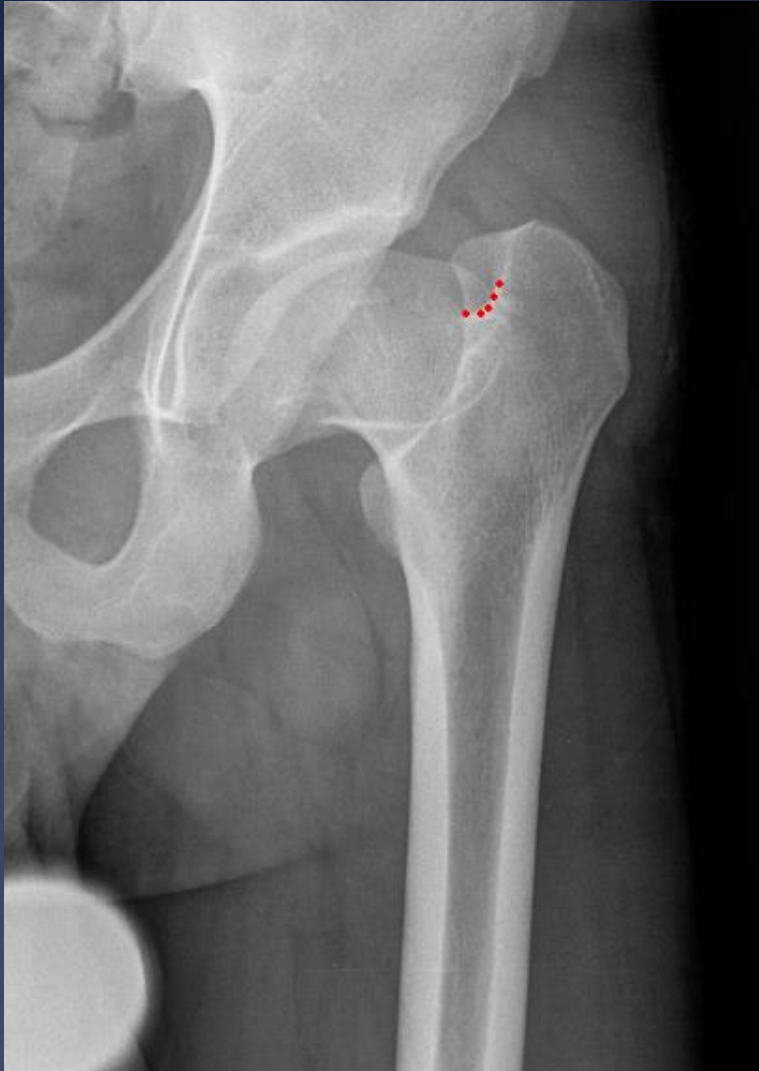




# Relative Neck Lengthening

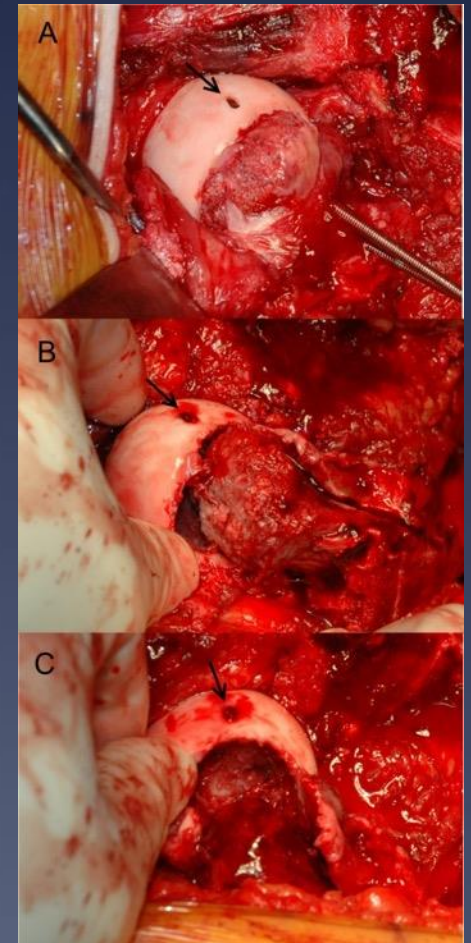
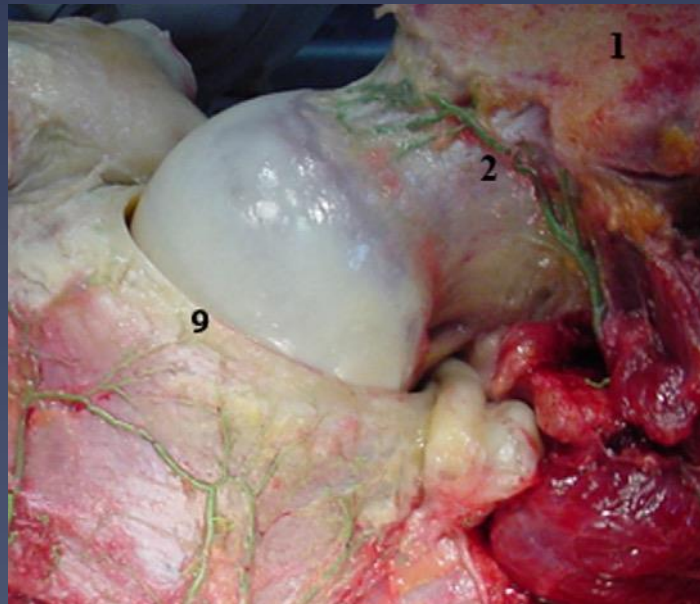


Preop → 6 mo Postop



# Subcapital Correction

- \* Leunig et al, 2007
- \* Surgical hip dislocation
- \* Retinacular dissection
- \* Loosen head through physis

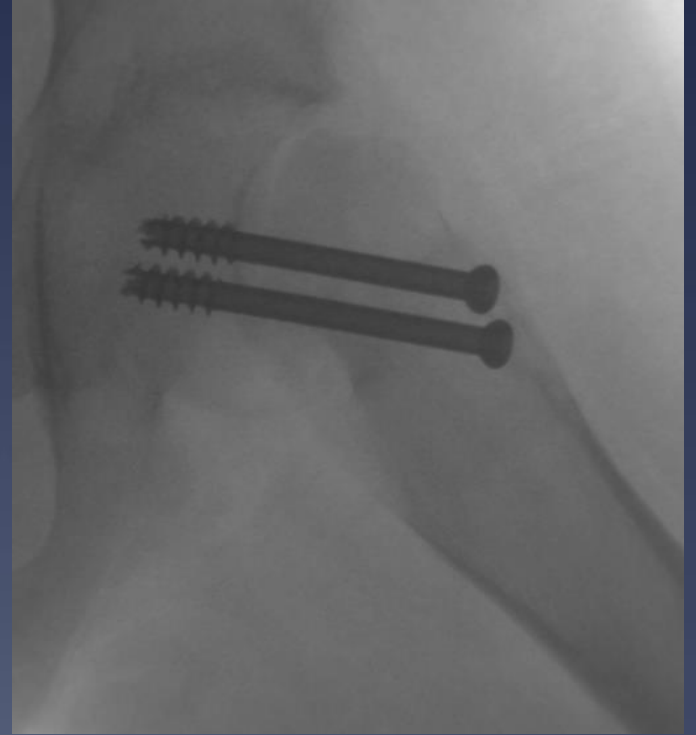
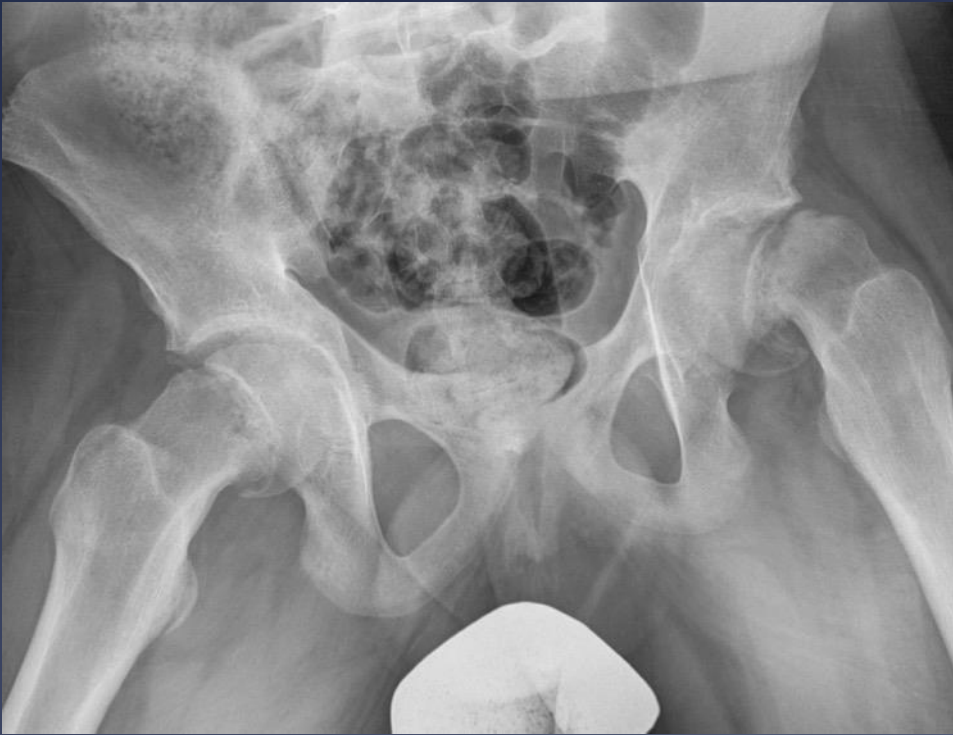

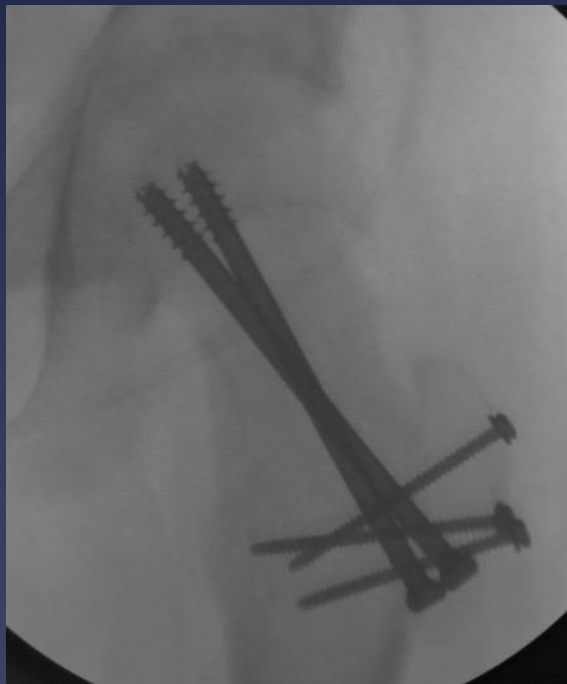


# Subcapital Correction

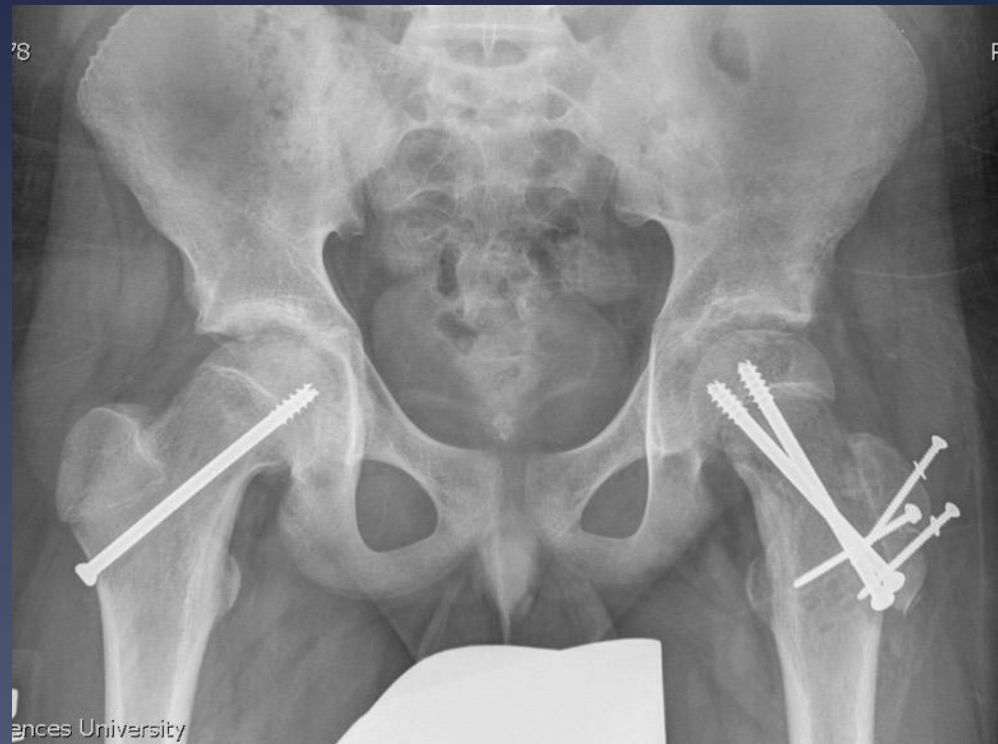- \* Slongo, et al. *J Bone Joint Surg Am*. 2010;92:2898-908
  - \* 23 cases, minimum 2 year follow-up
  - \* 21 excellent outcomes clinically and radiographically
  - \* 2 cases of OA and ON
- \* Sankar, et al. *J Bone Joint Surg Am*, 2013 Apr 03;95(7):585-591
  - \* 27 unstable SCFE, 22 mo average f/u
  - \* 26% osteonecrosis; 15% broken implants
- \* Ebert, et al. *Orthop Surg Res*. 2019 Nov 8;14(1):349. †
  - \* Severe chronic and severe acute on chronic SCFE
  - \* 15 cases, 100% anatomic reductions, 11 excellent results, 4 AVN (26%)
- \* Indications/limitations not completely delineated

15 yo male: acute on chronic



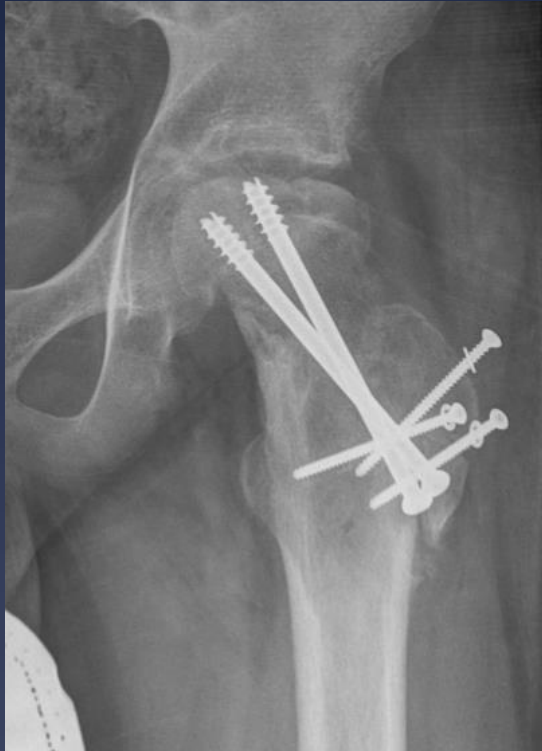

\* Intra-op

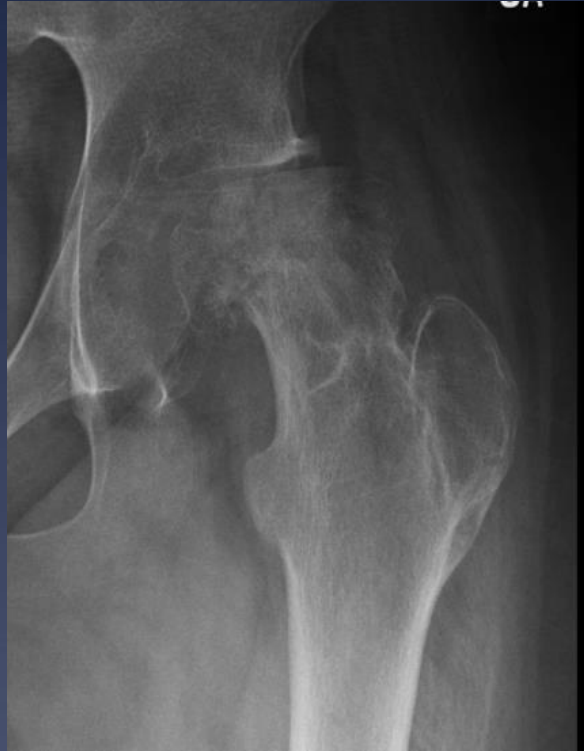

2 months

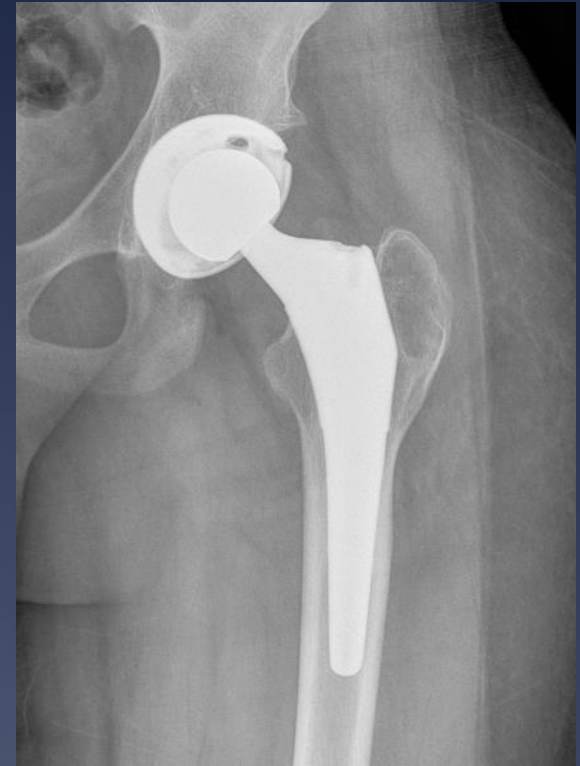



\* 4 months



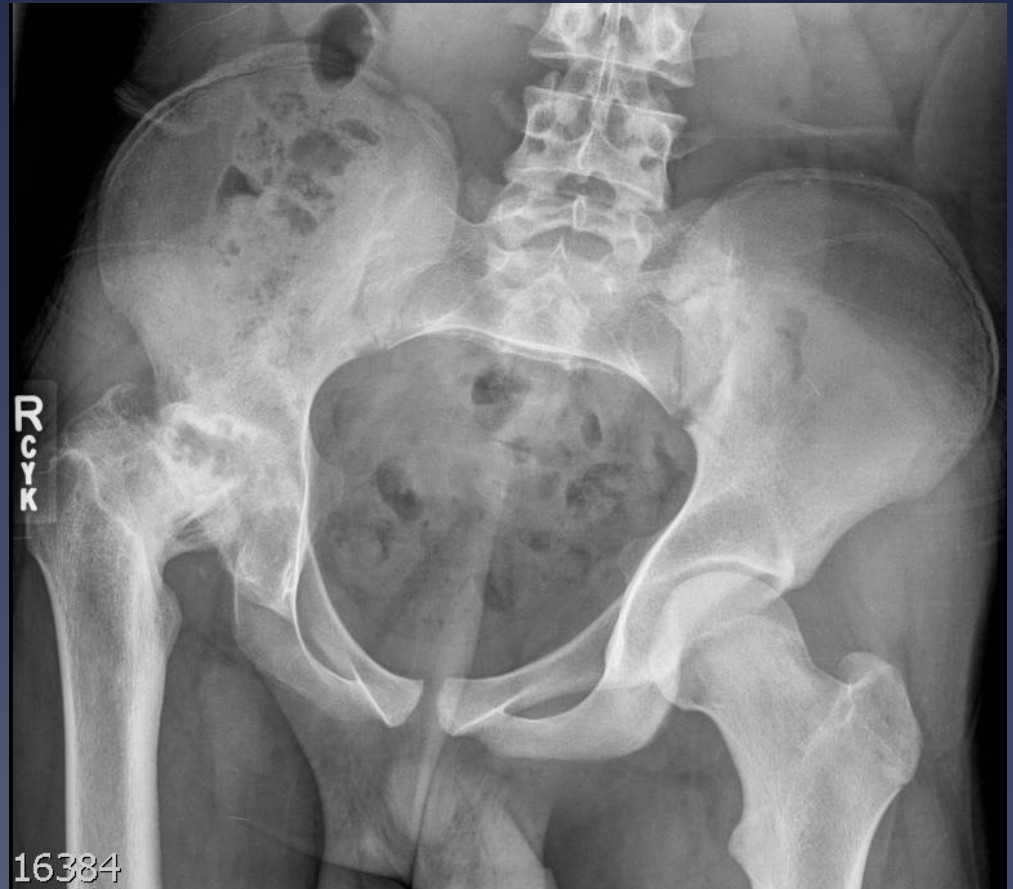13 months



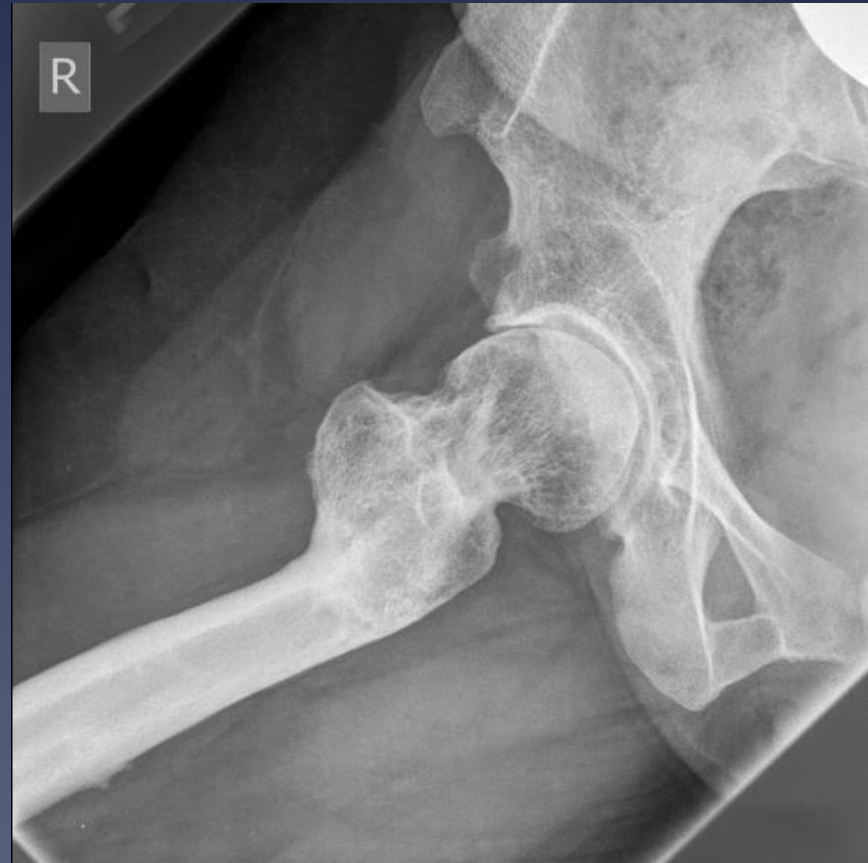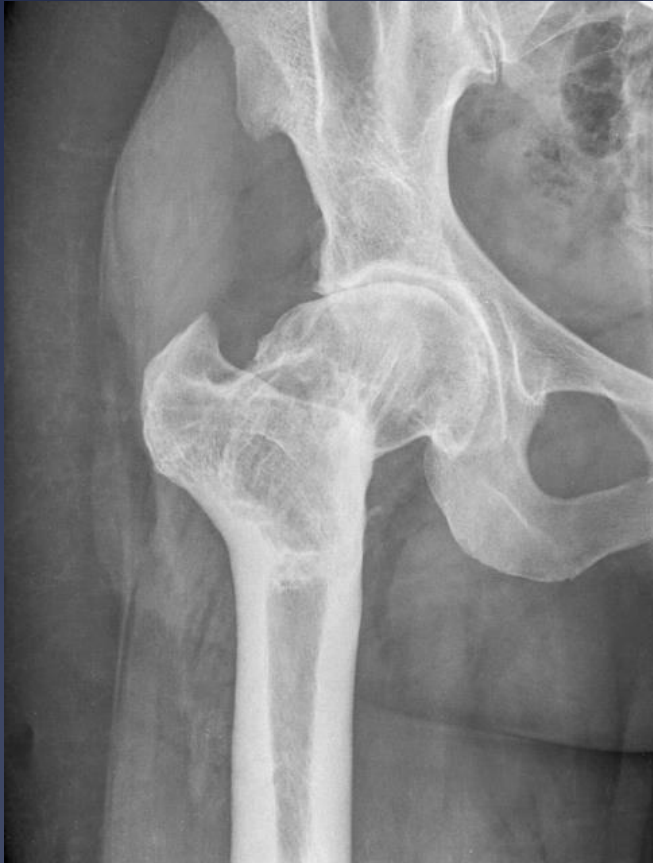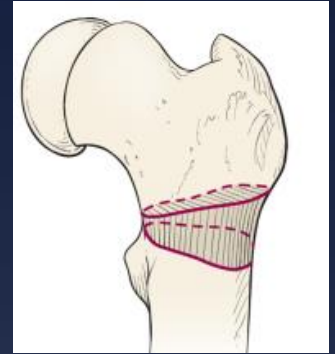18 years old

# 18 yo male

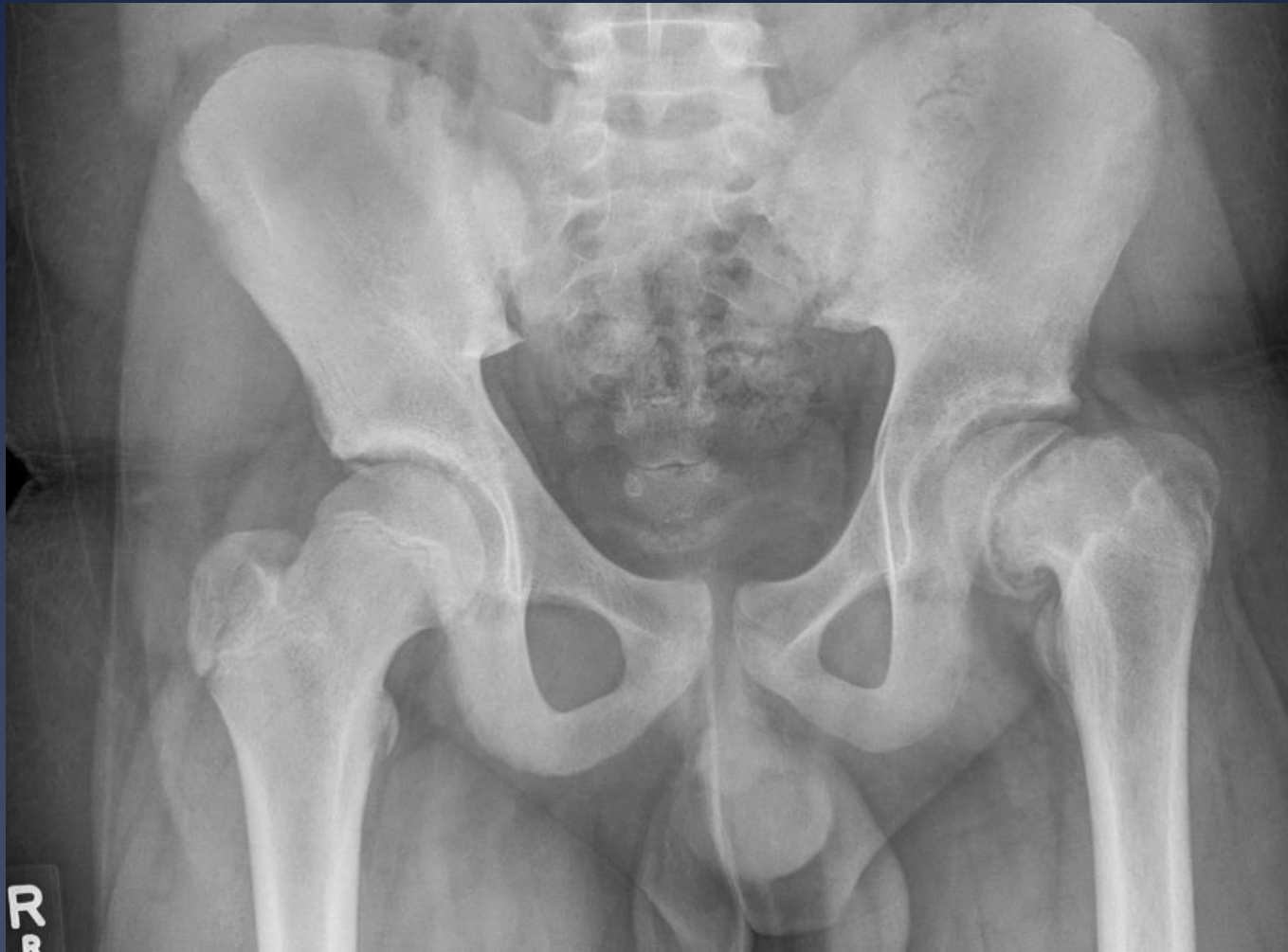- 3 years s/p in situ pinning
- Graduating HS, on high dose narcotics and applying for disability



40 yo female: s/p Southwick

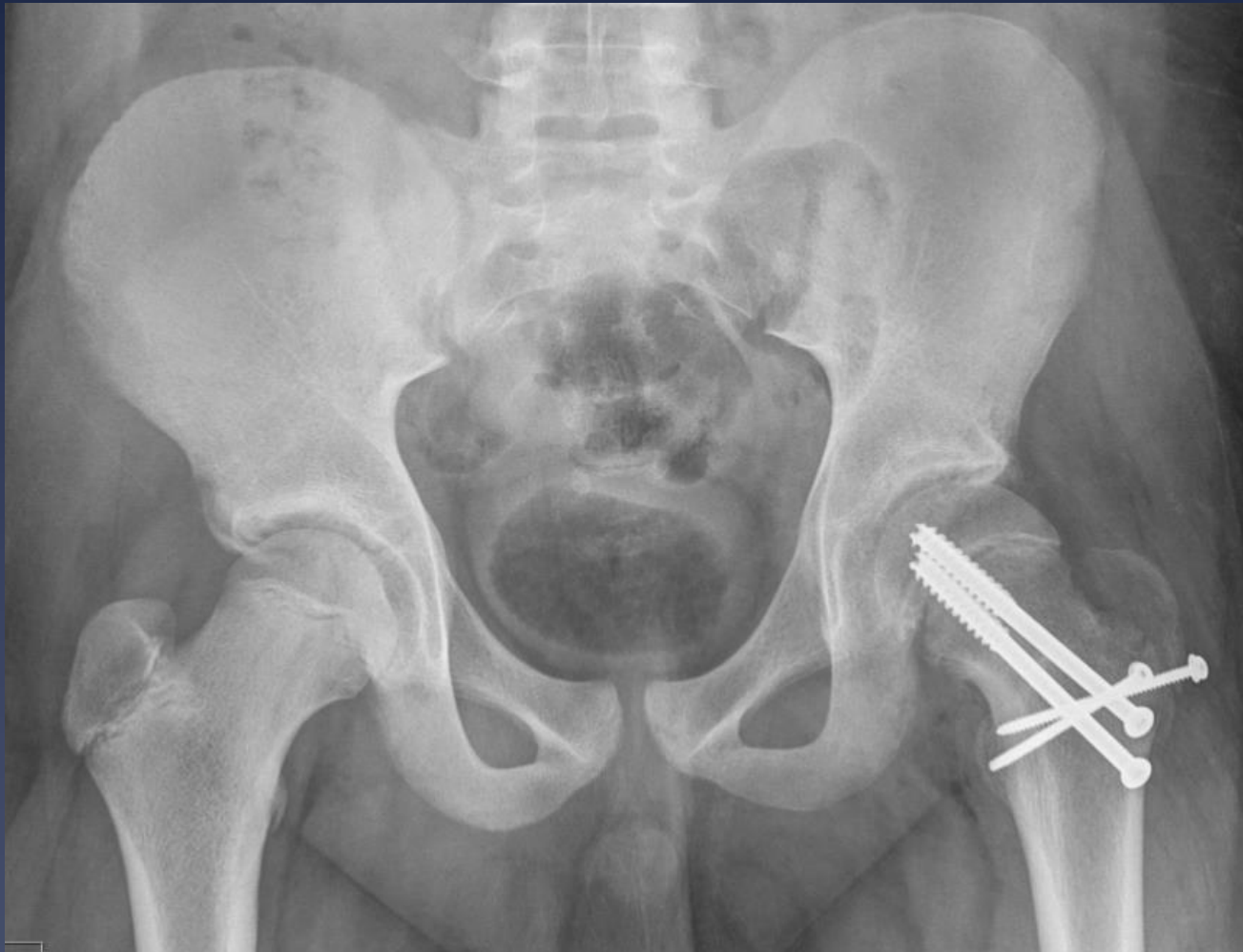

12 yo male

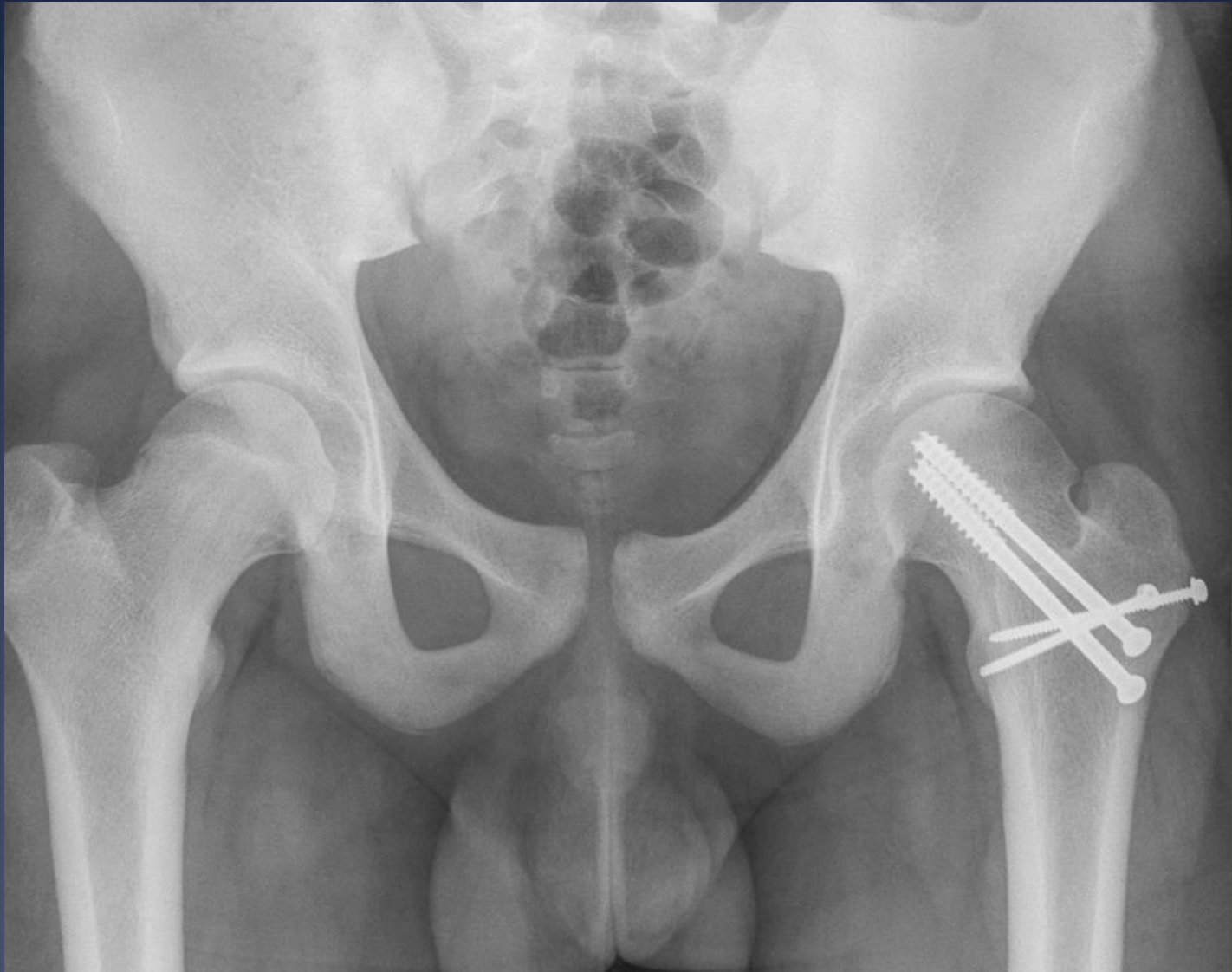



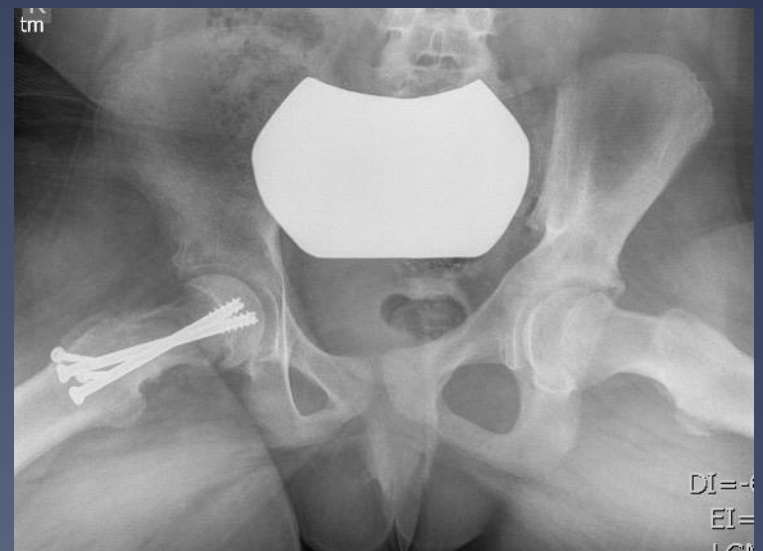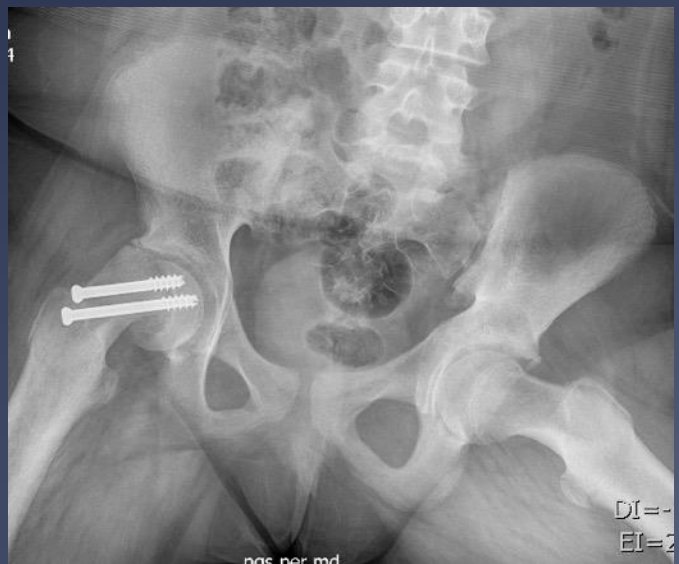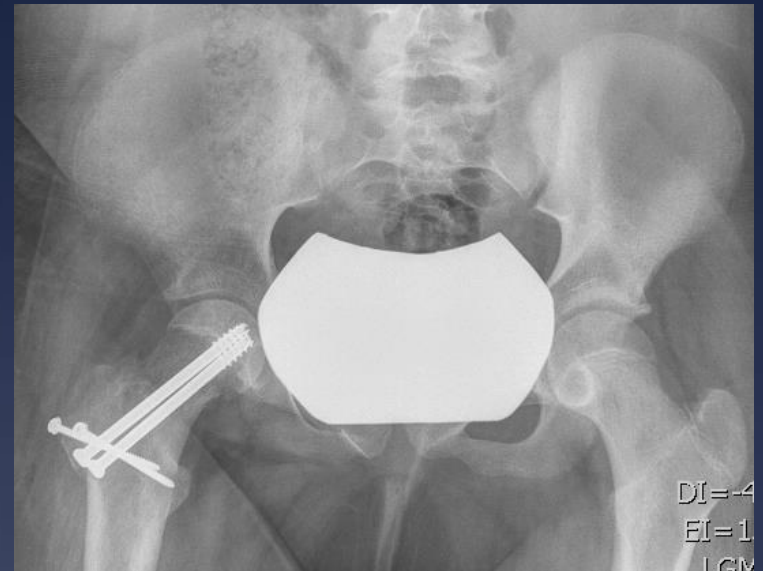
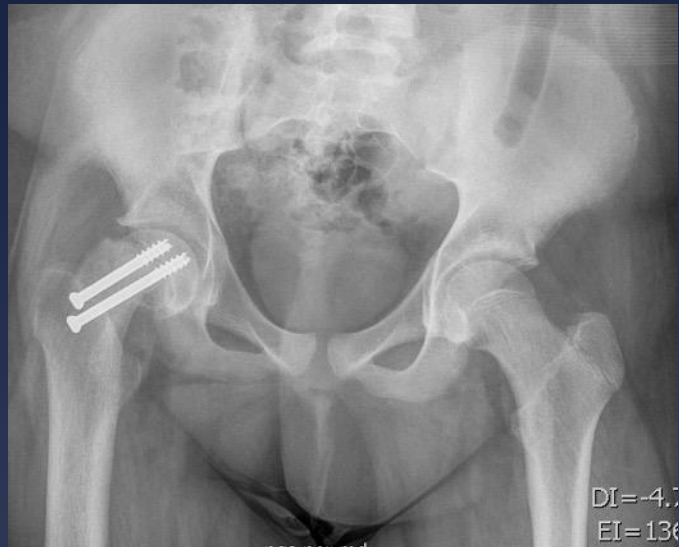# Immediate Postop



22 months Postop



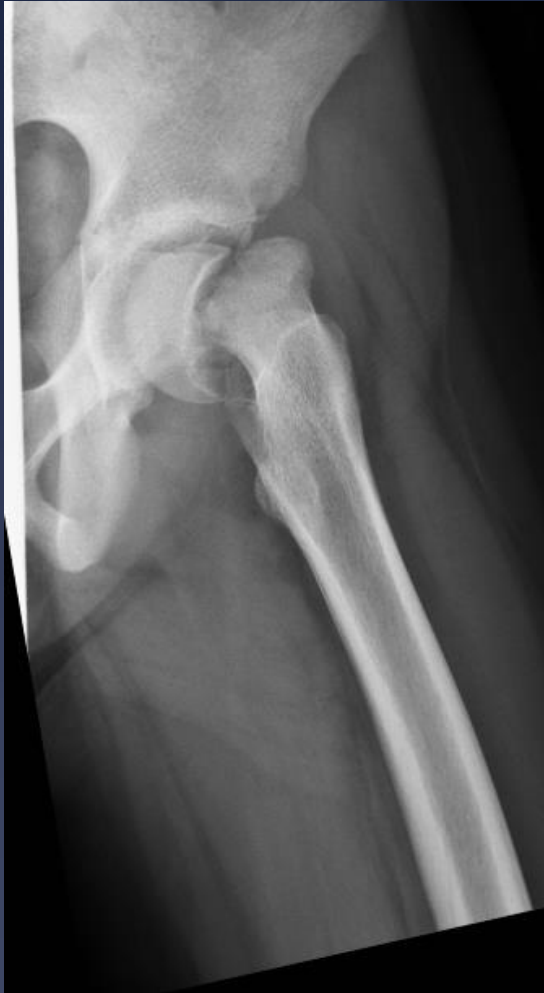# 12 yo female



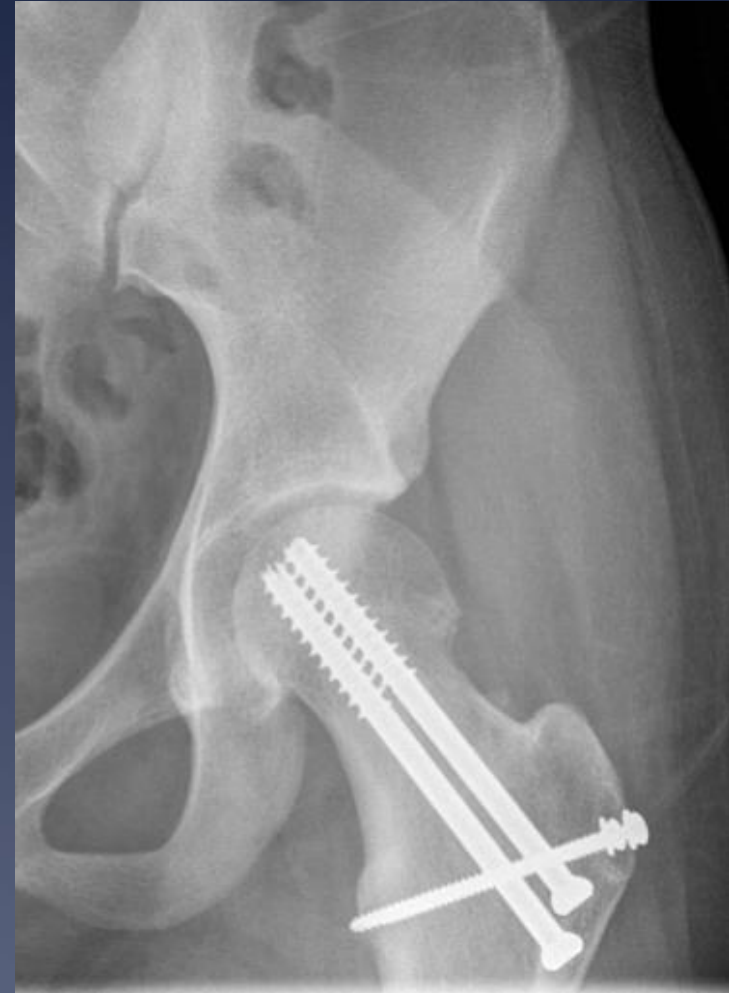\* Presentation

2 months postop

11 yo female



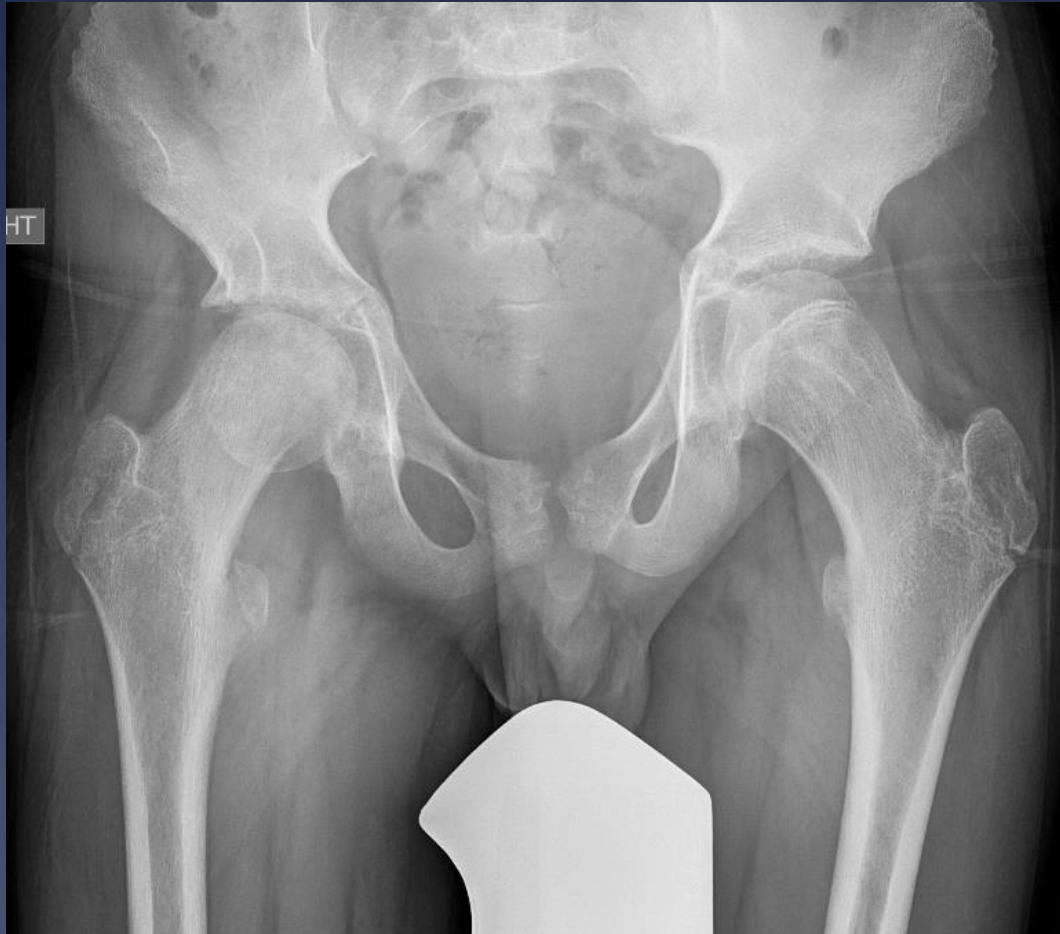\* Presentation



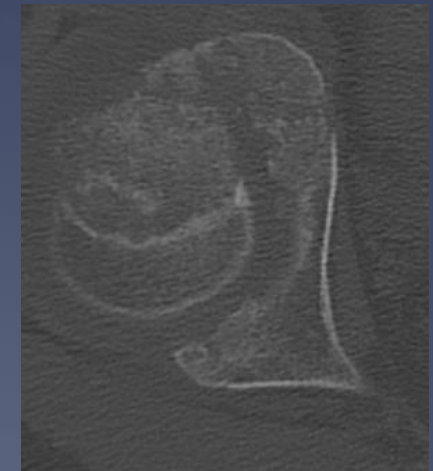
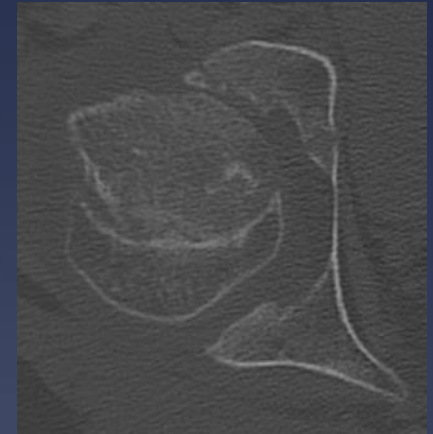
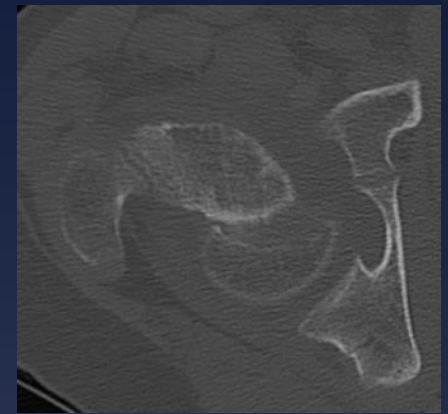
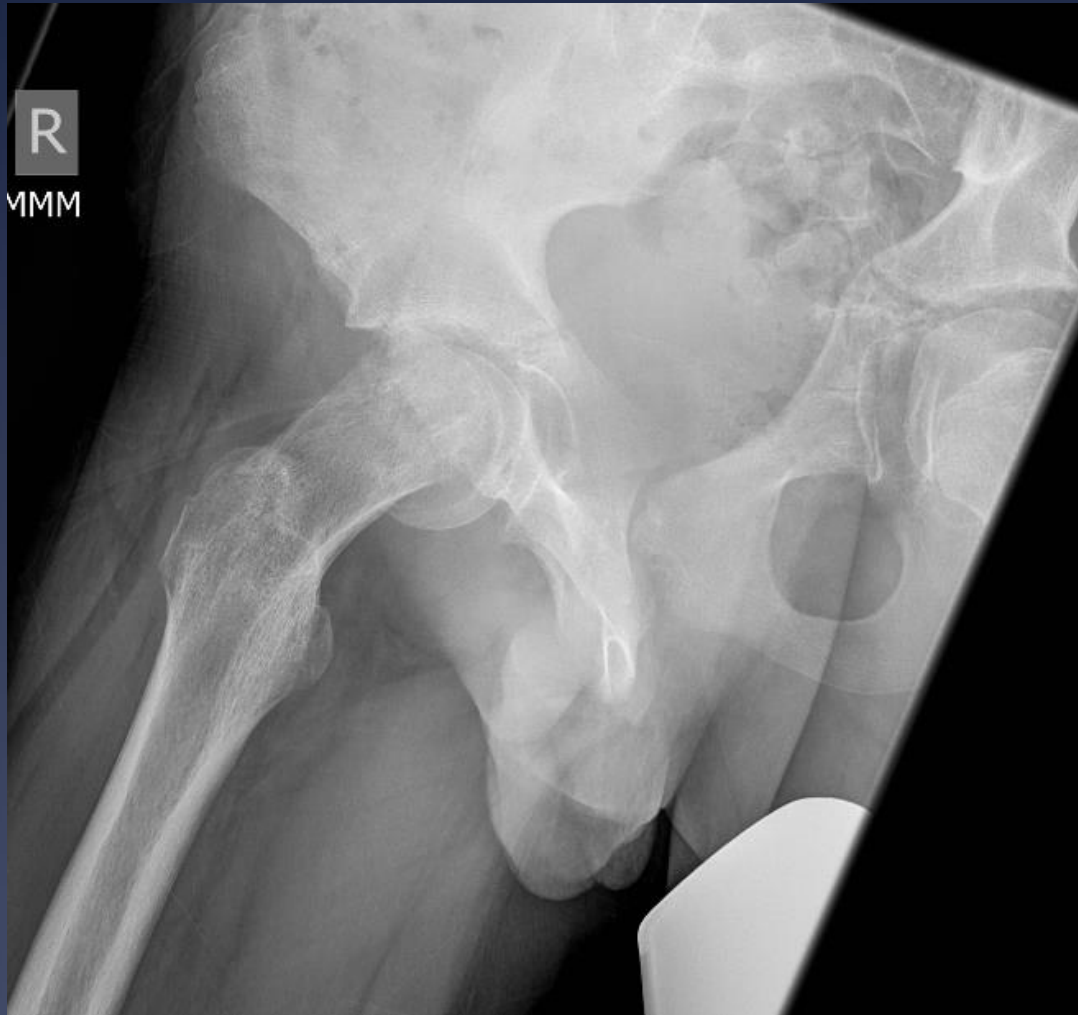1 year Postop



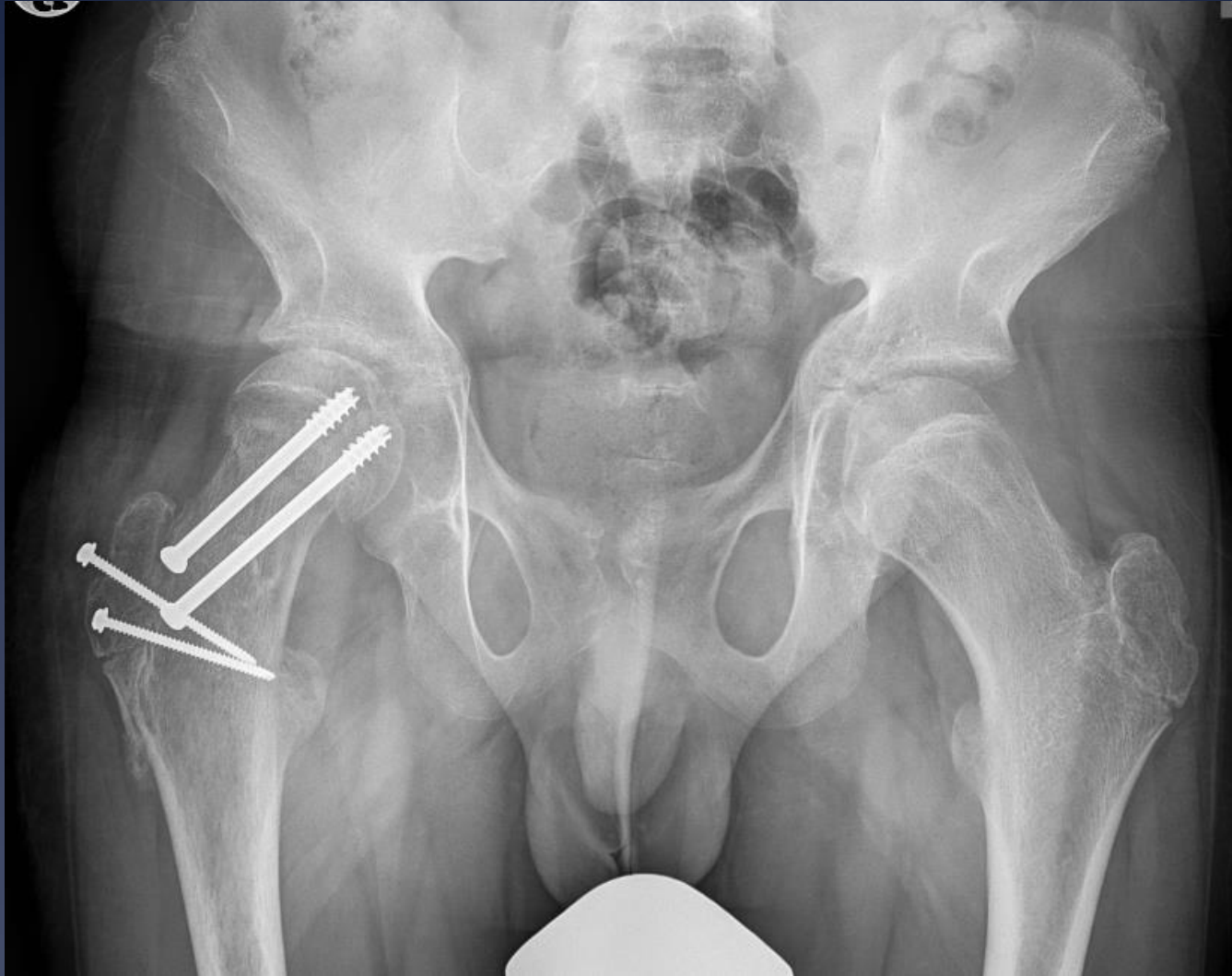
24 yo male with 3 months right  
hip pain

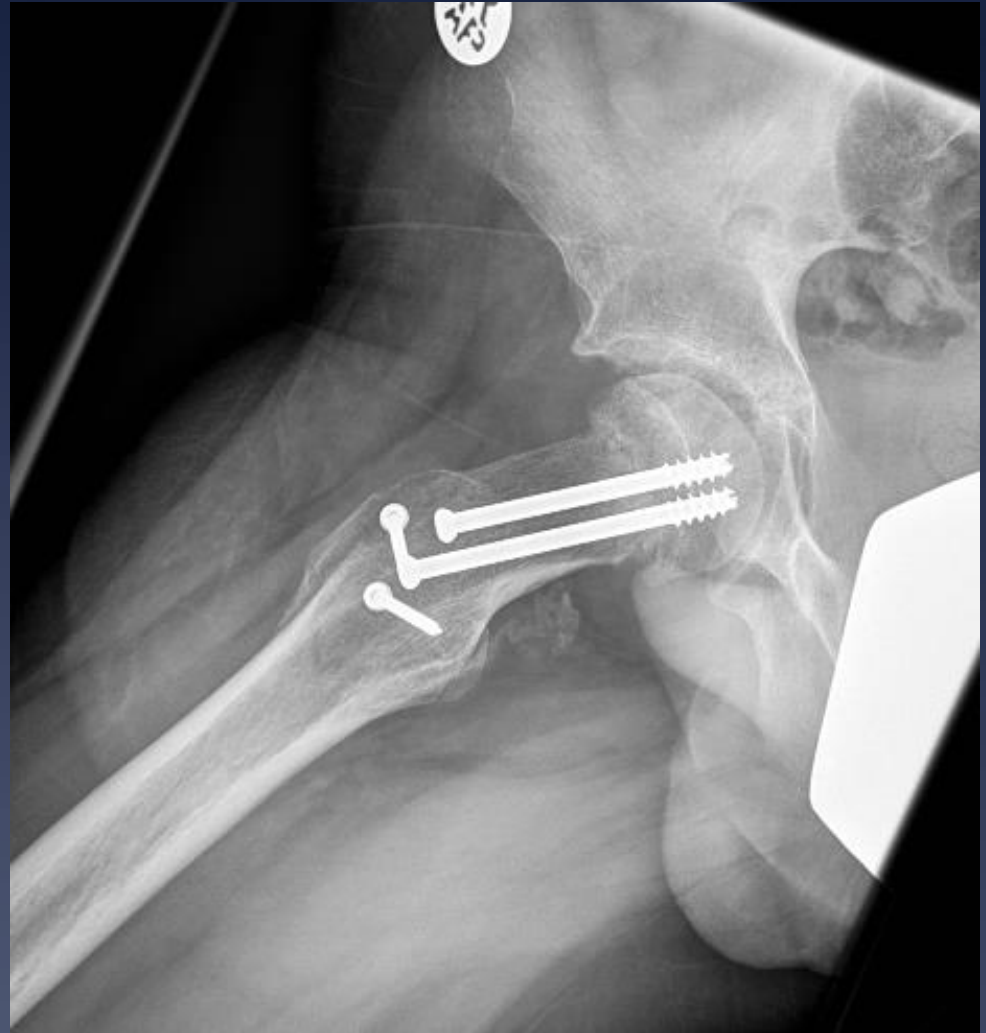
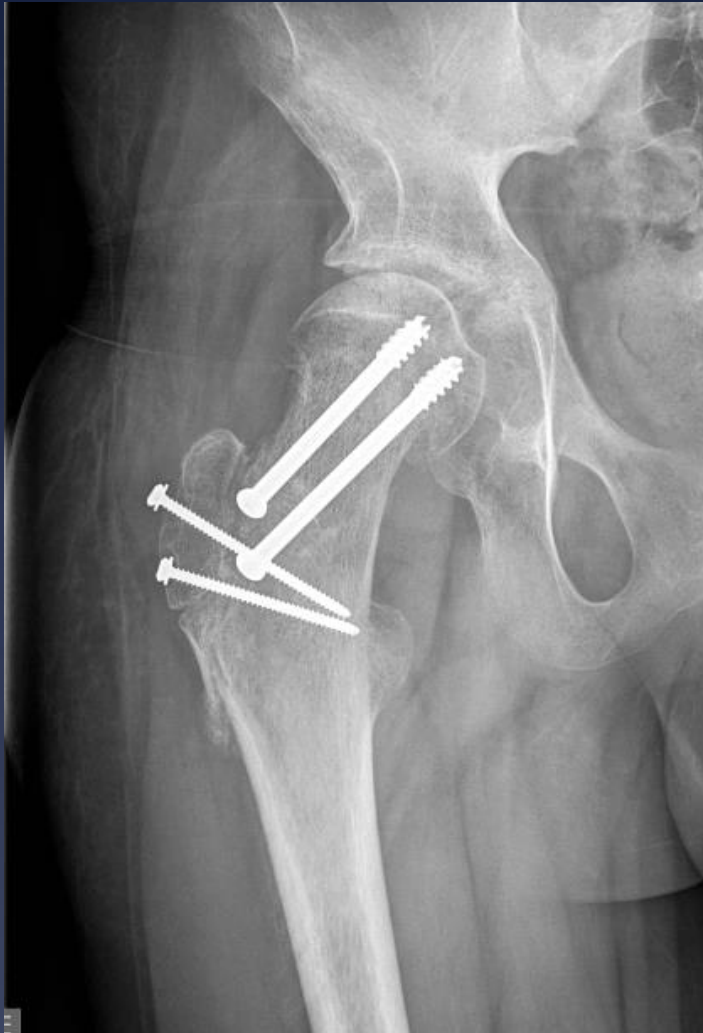
# Lateral view & CT



# Femoral Neck Osteotomy

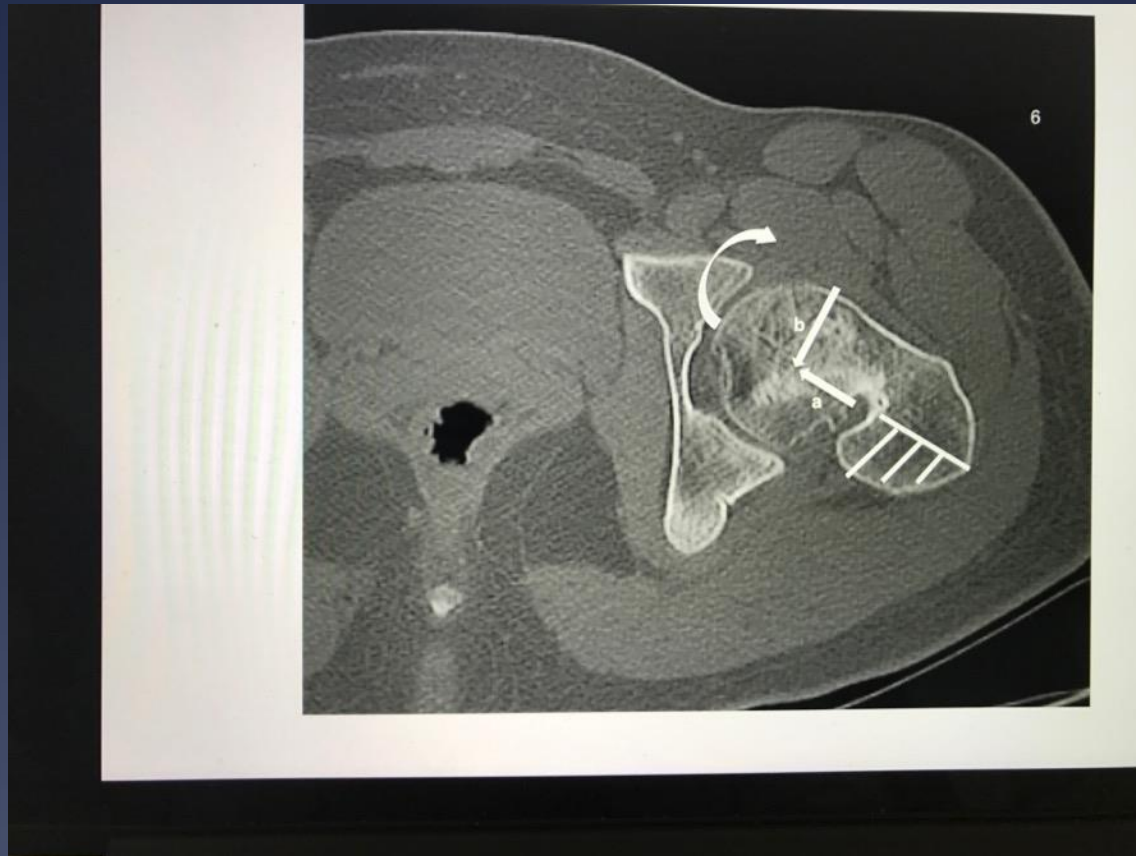


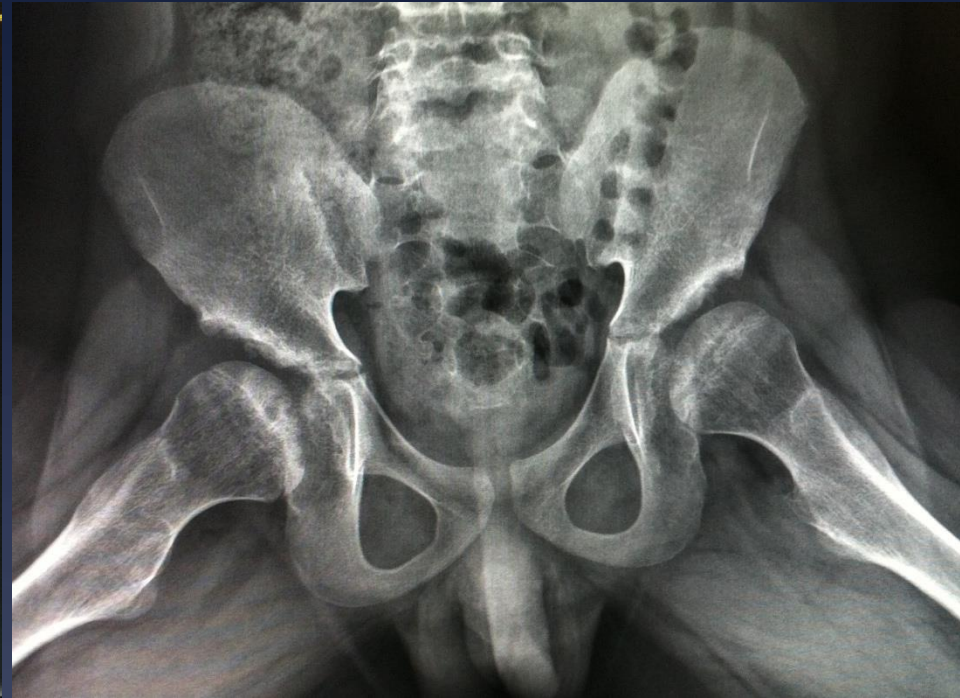
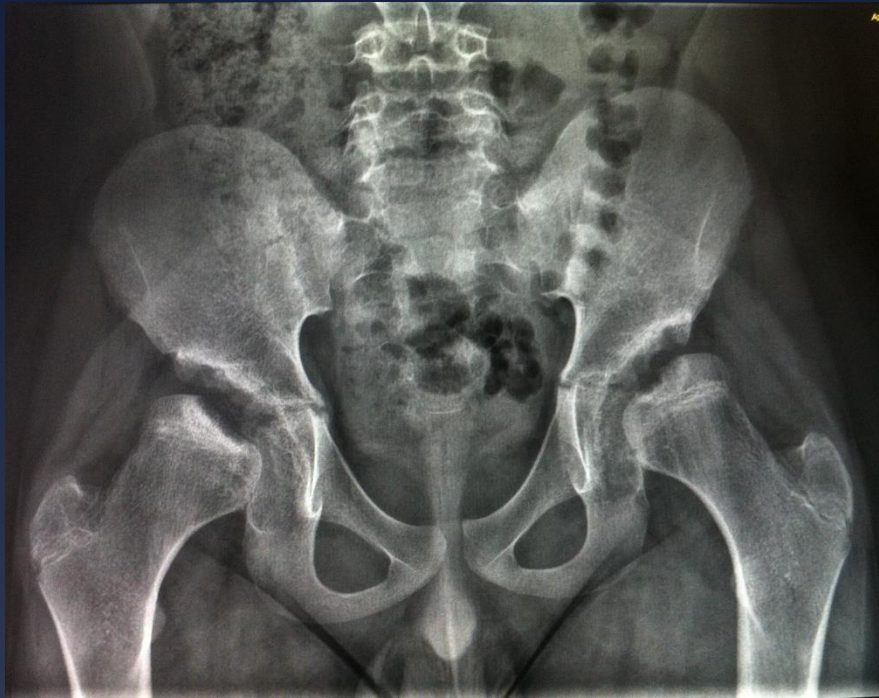2 months postop, reports no pain and has excellent motion



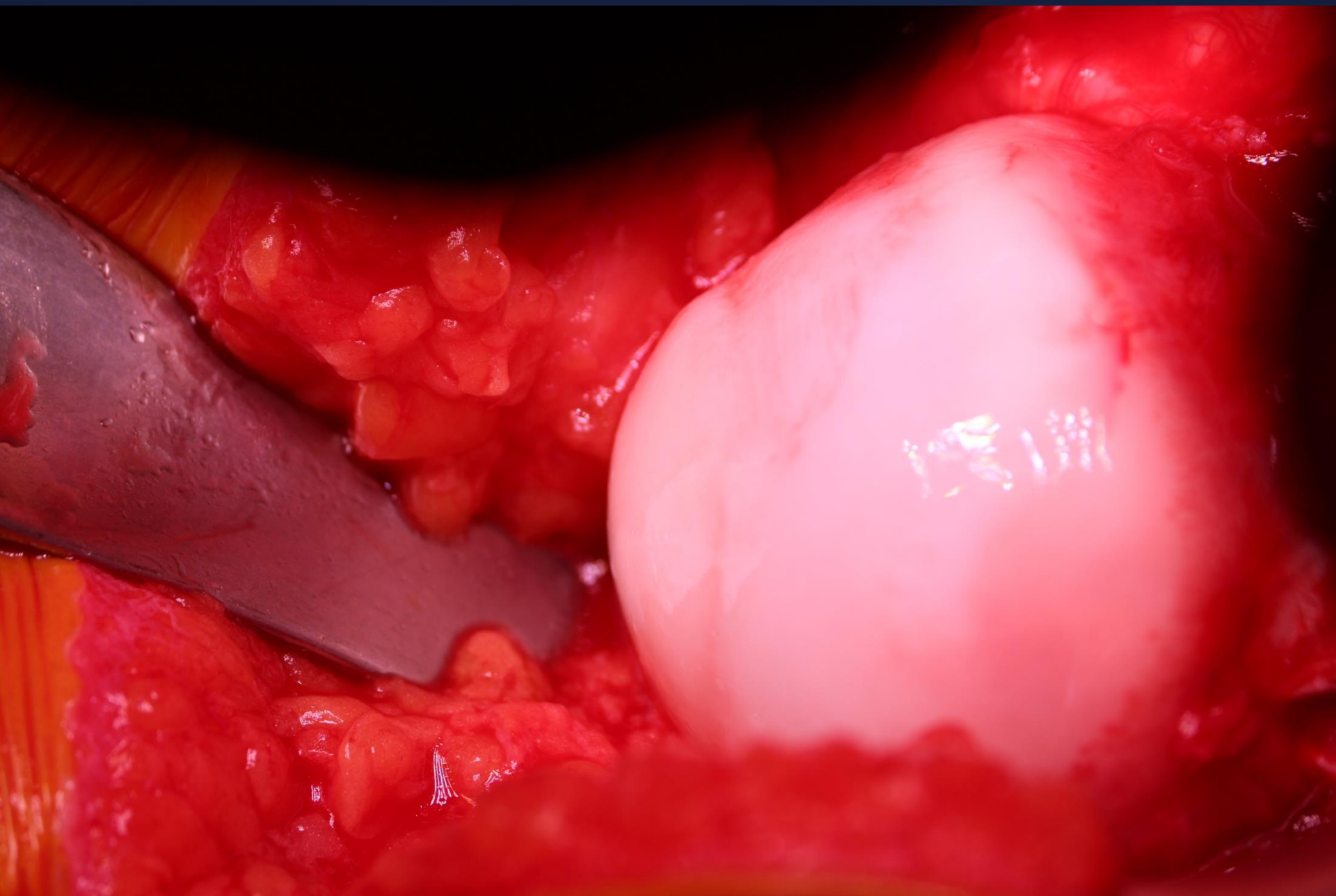
# Osteotomy for Healed Severe SCFE



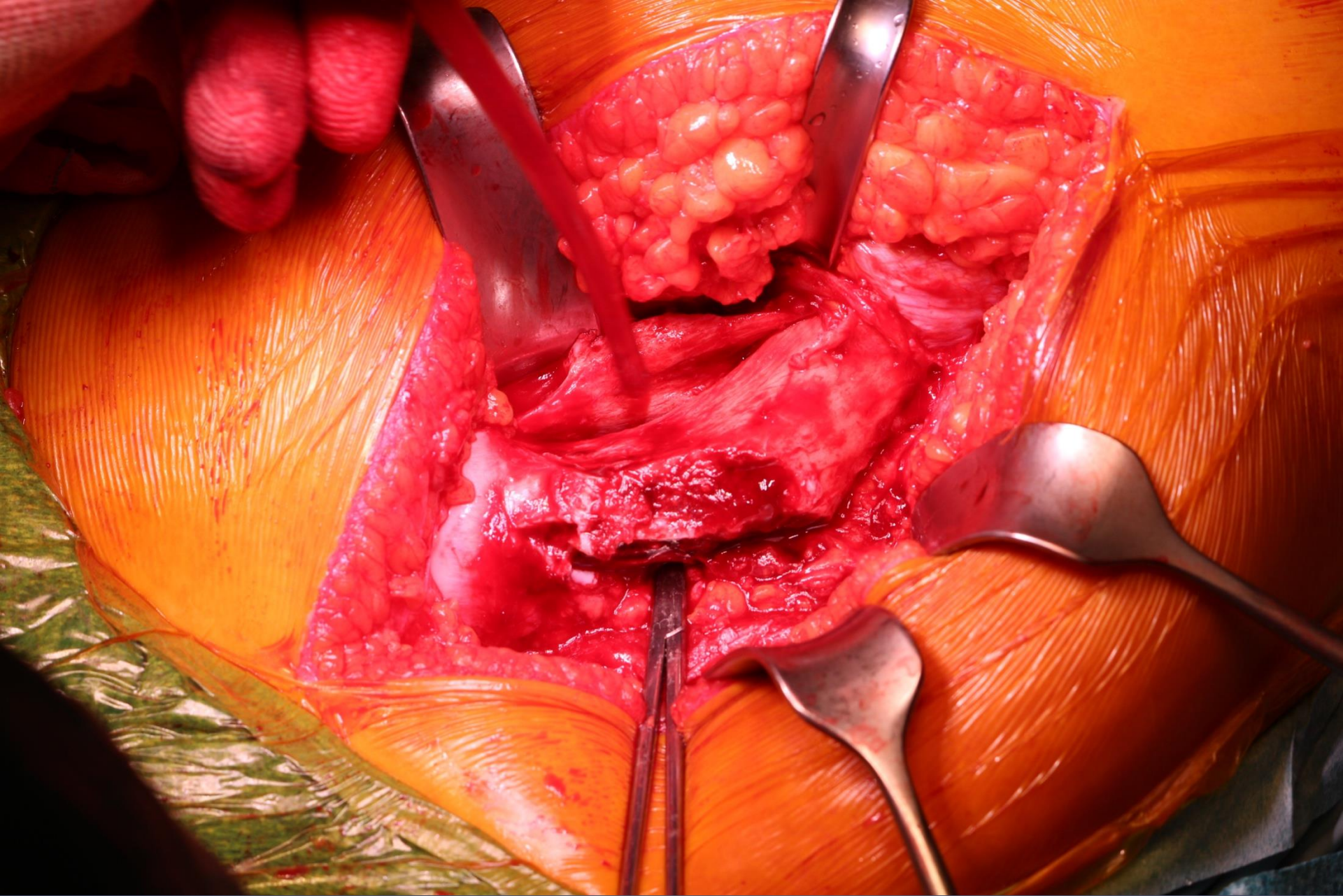


Patient presented by Dott. Dibello Daniela  
Garzotto Mattia 12 y. old

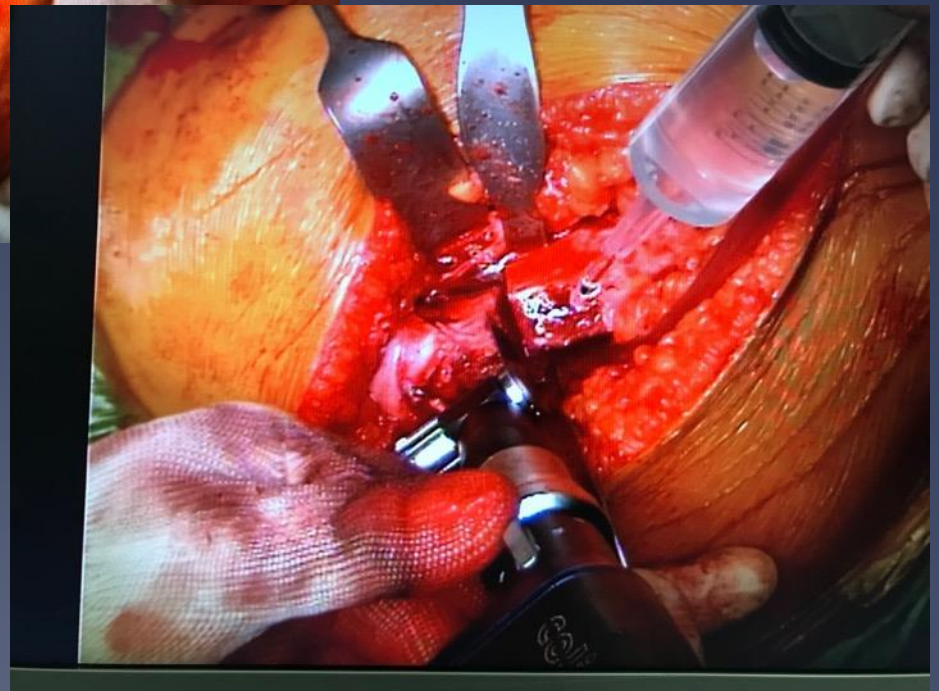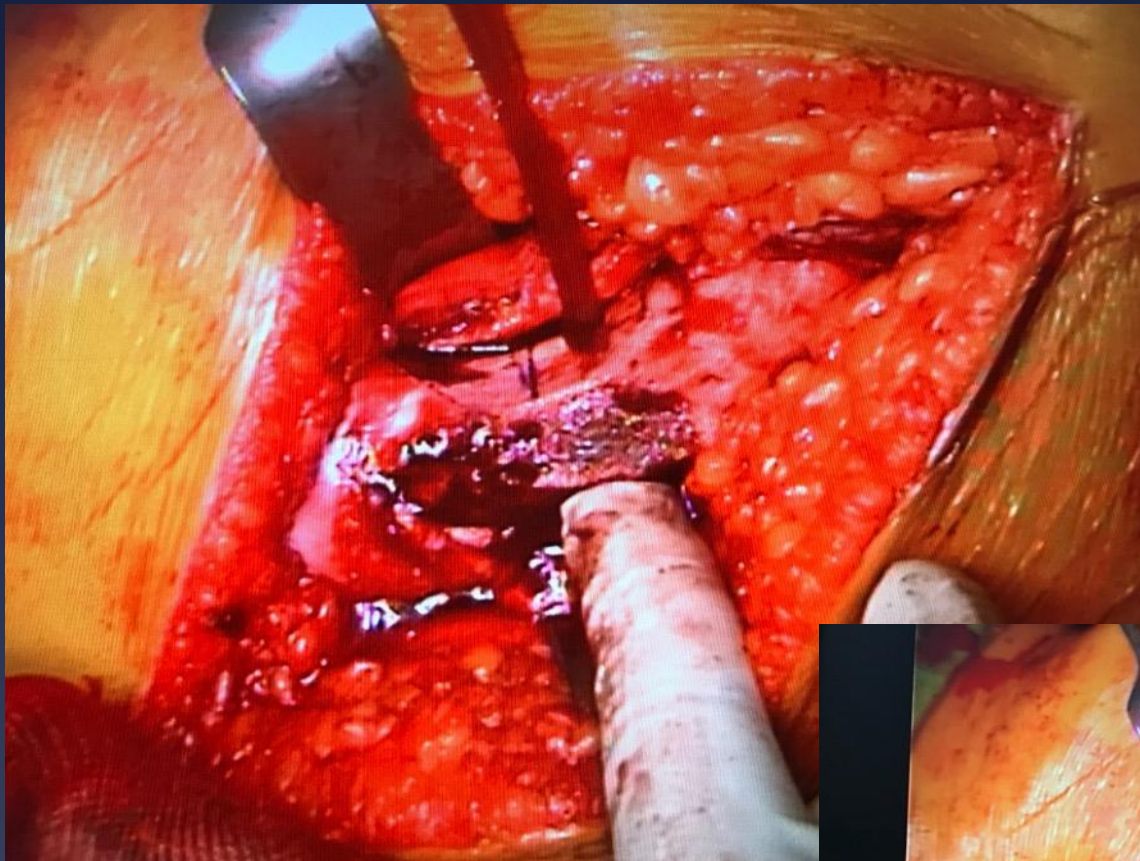
You evaluate this patient during your visit in Portogruaro and  
promise  
to his family To treat him but I forgot your **Surgical**  
**indications: FNO+PAO**



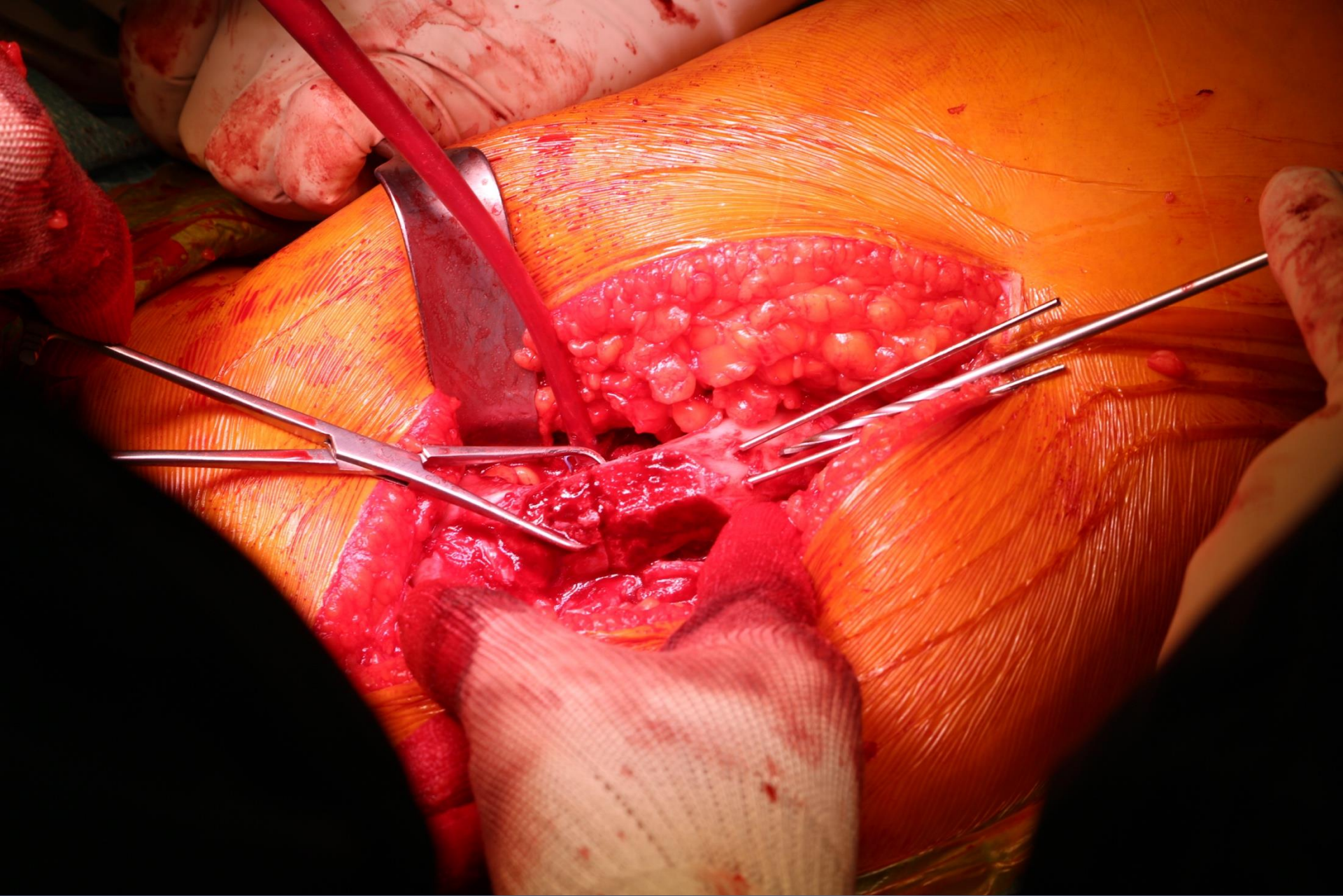




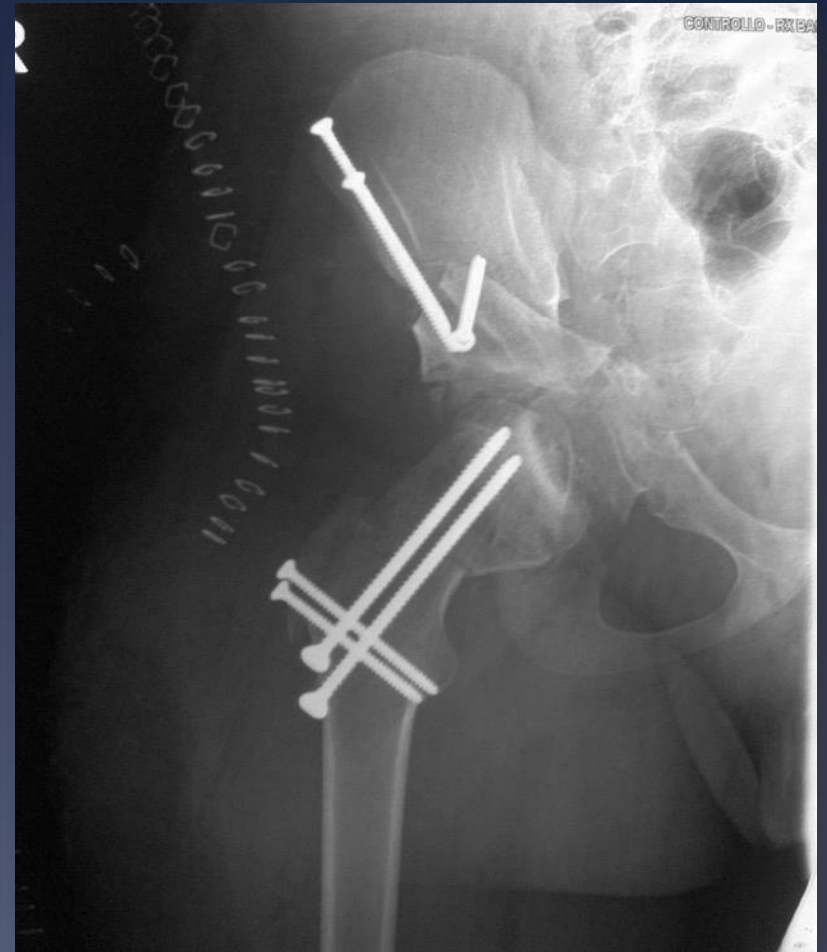
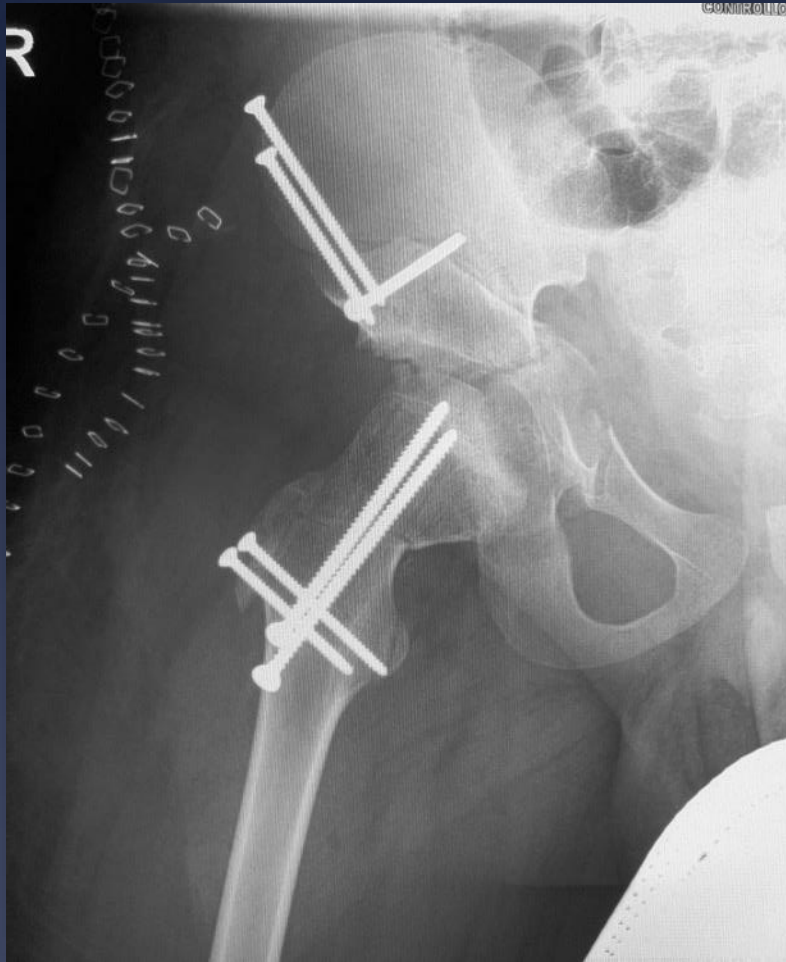








# POD 0 s/p PAO and FNO





# Femoral Head Reduction Osteotomy

## CARD

Computer Assisted Research & Development

Liberato

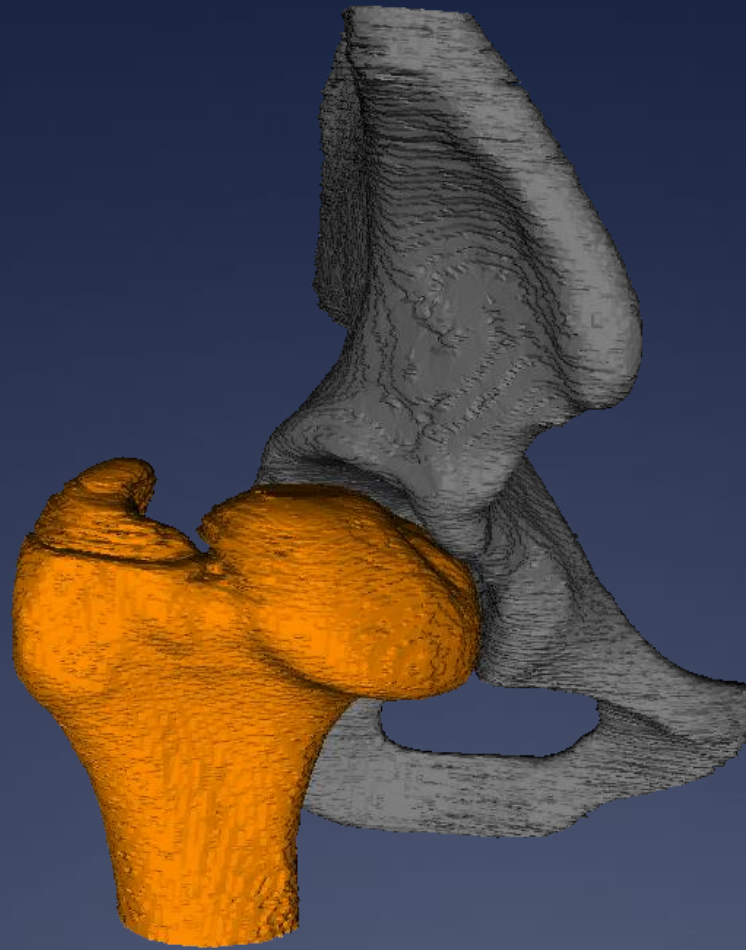


## 3D OP Planning

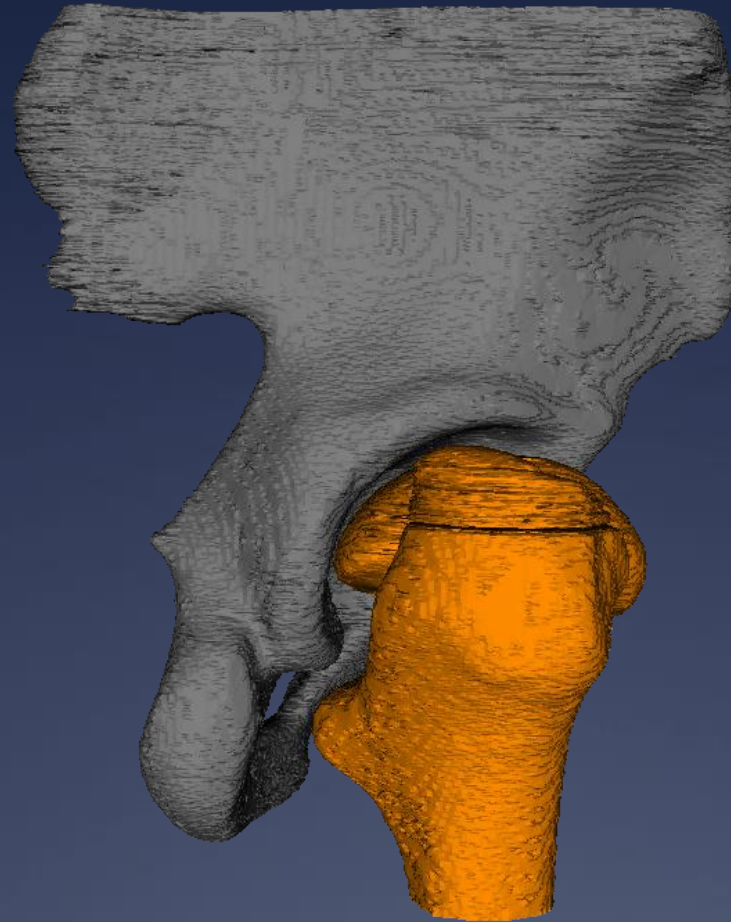
27.09.2025








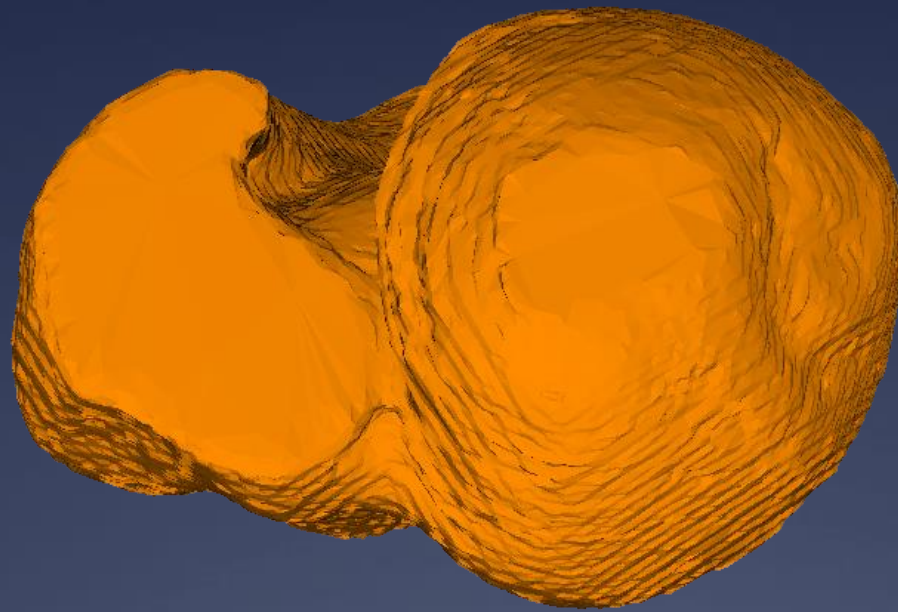
Preop Situation



Preop Situation




Preop Situation

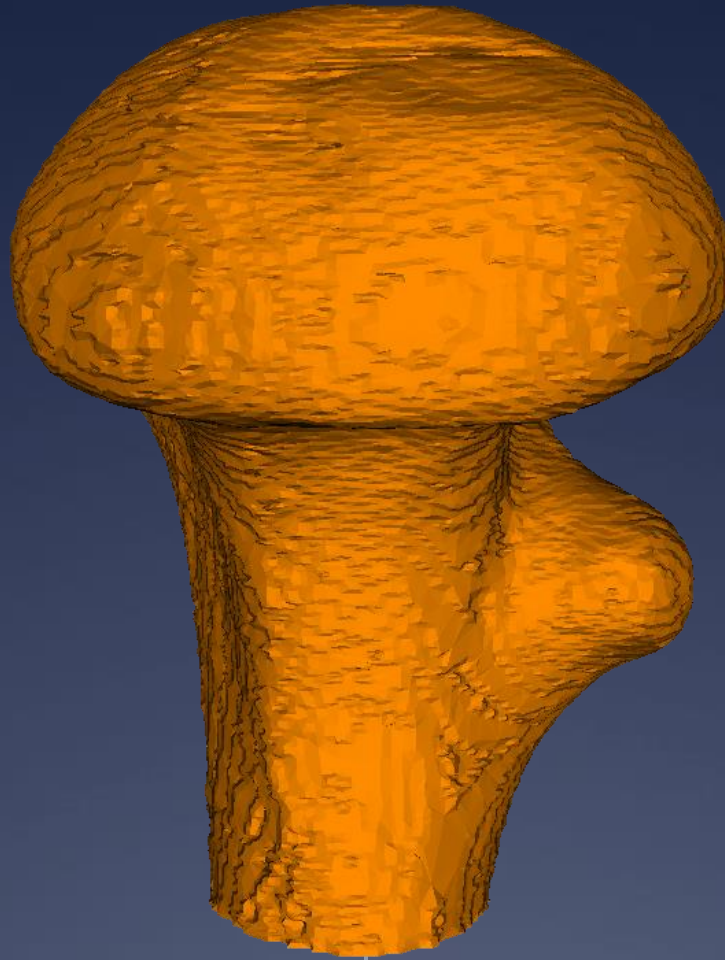


Preop Situation

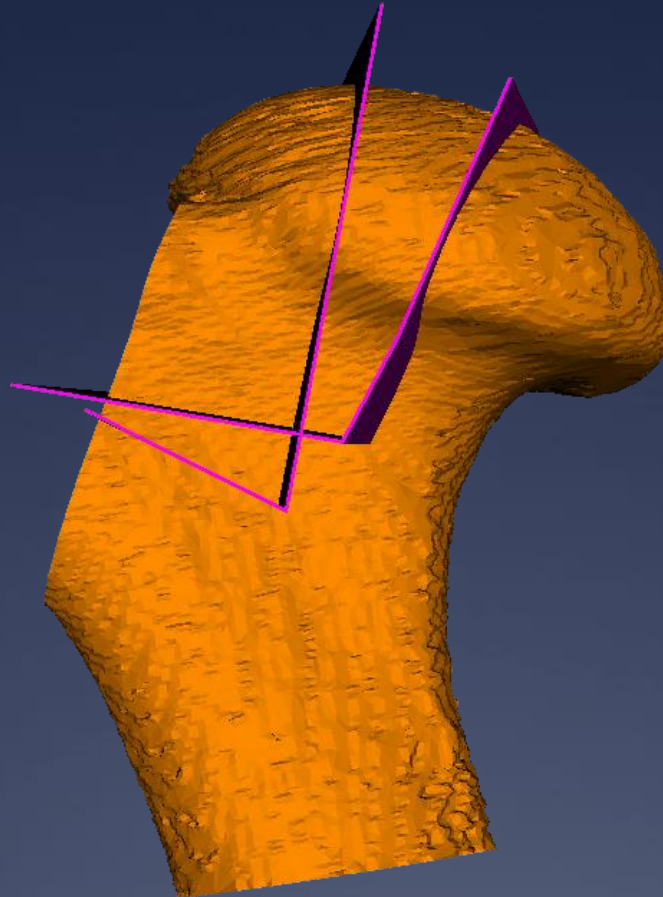





# Preop Situation



Preop Situation



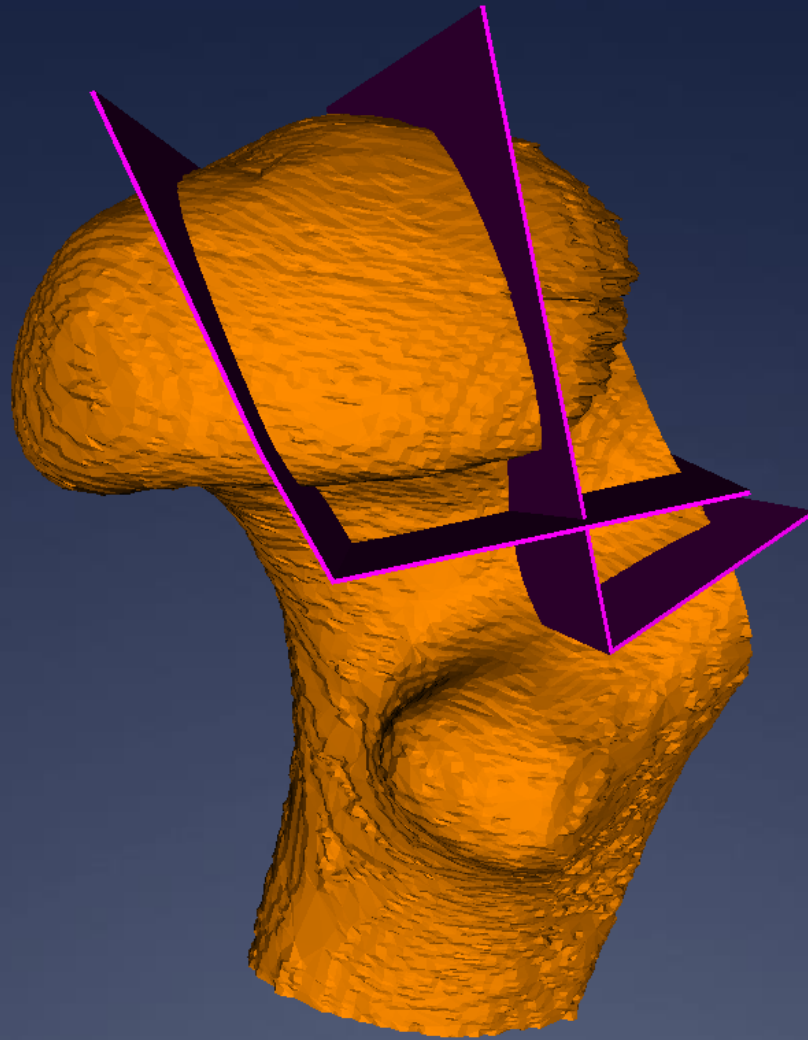
# Cutting planes



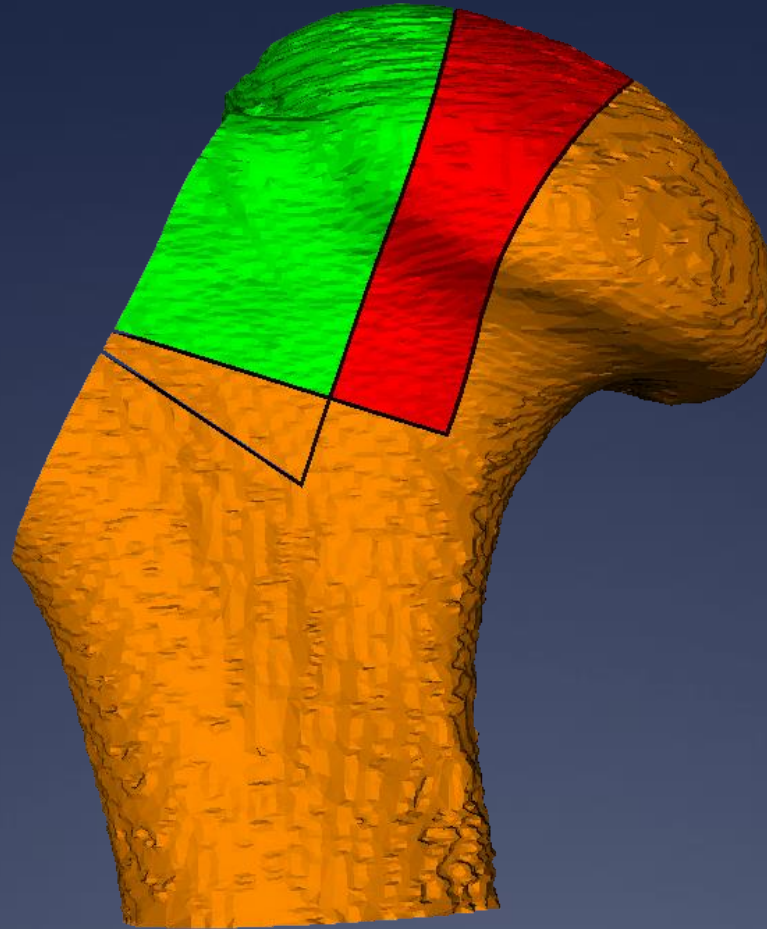
# Cutting planes

27.09.2025

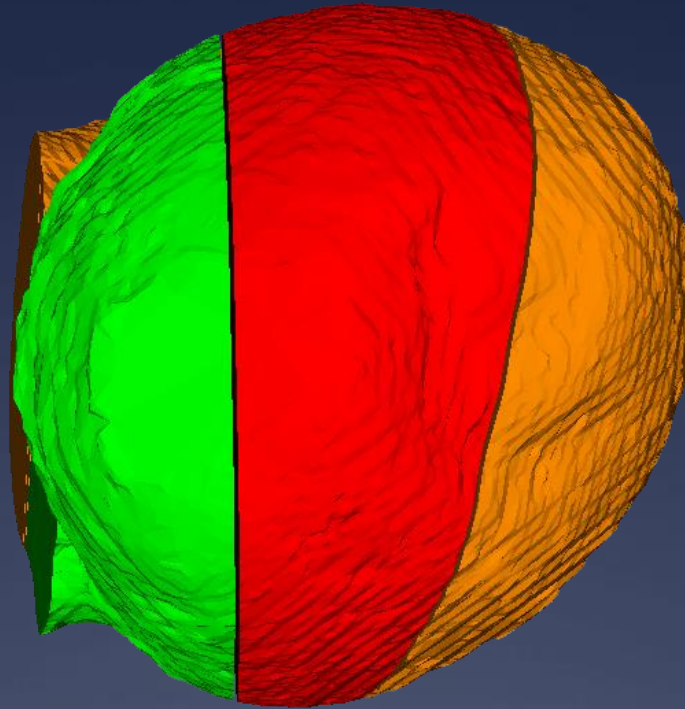




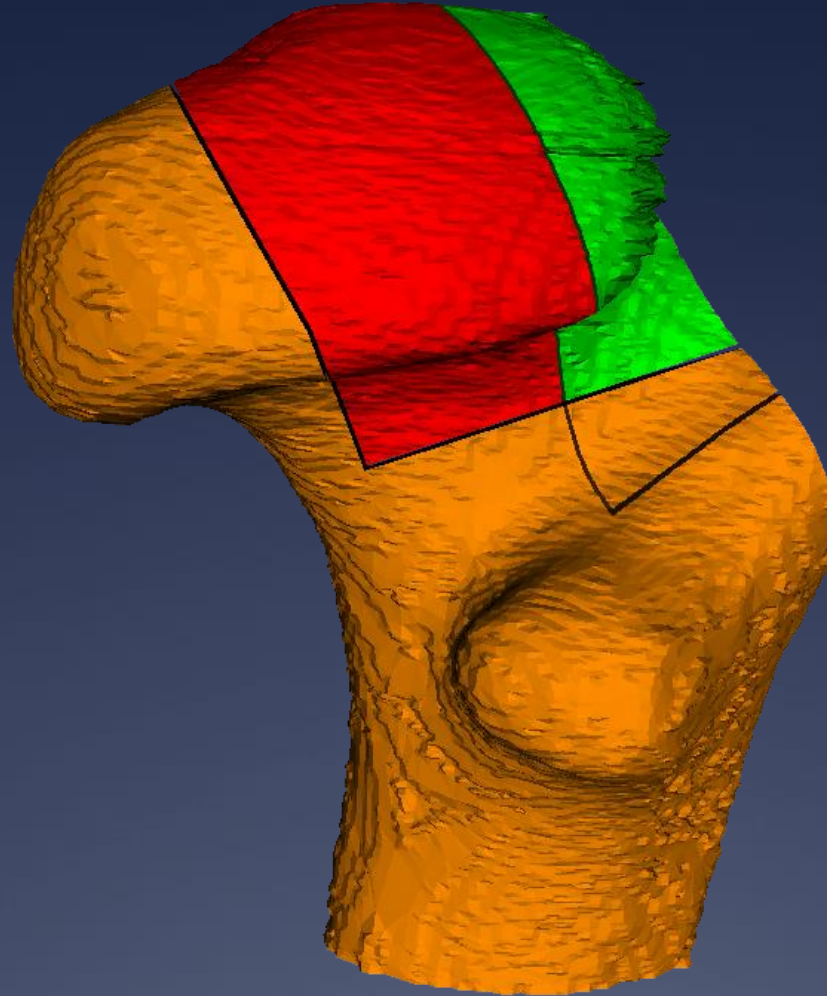
# Cutting planes



After cutting

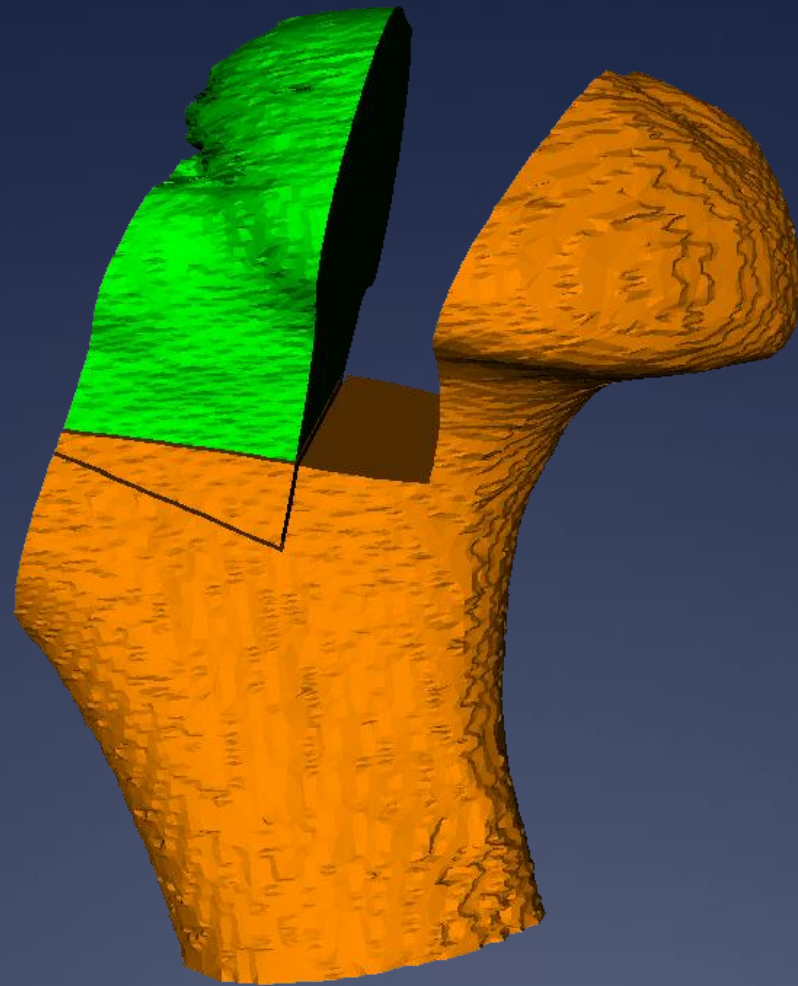


After cutting




After cutting

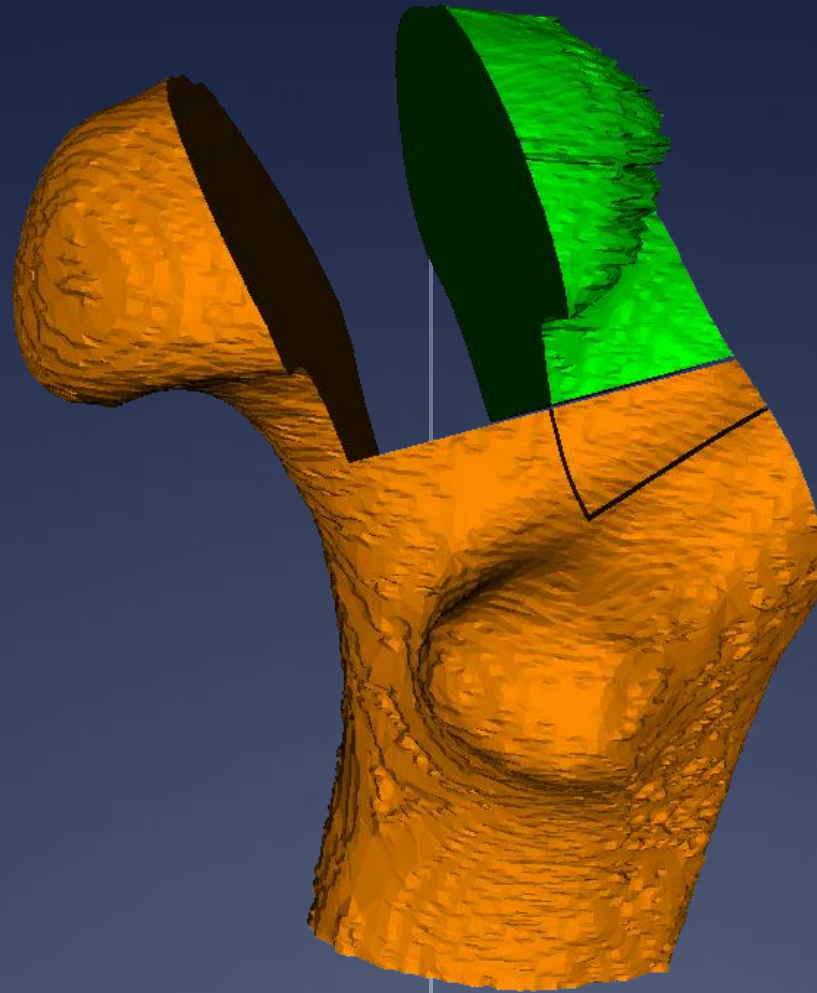




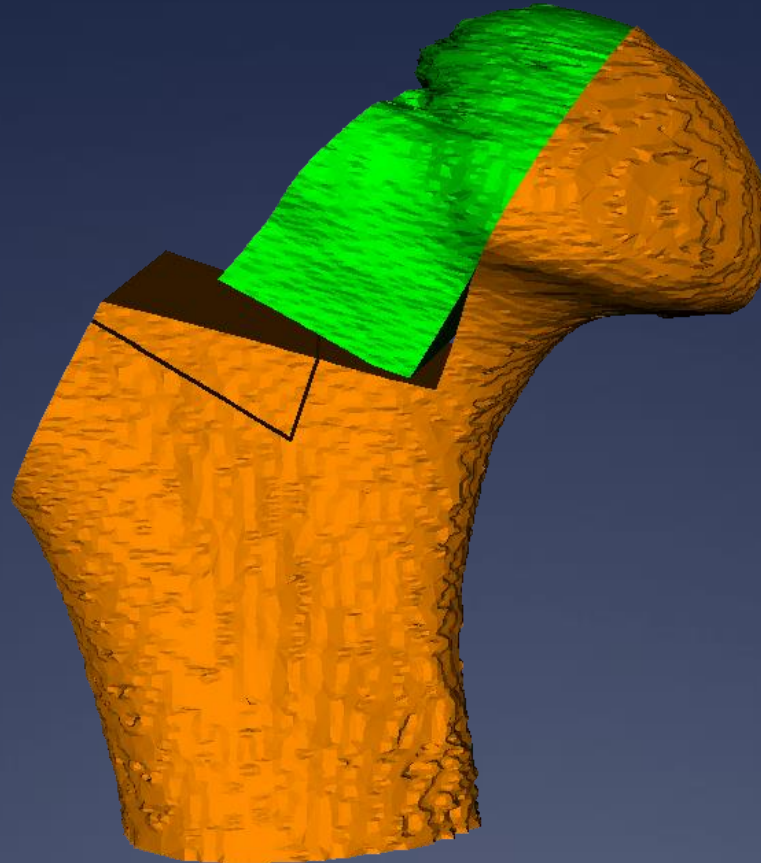
After cutting without wedge



After cutting without wedge




After cutting without wedge



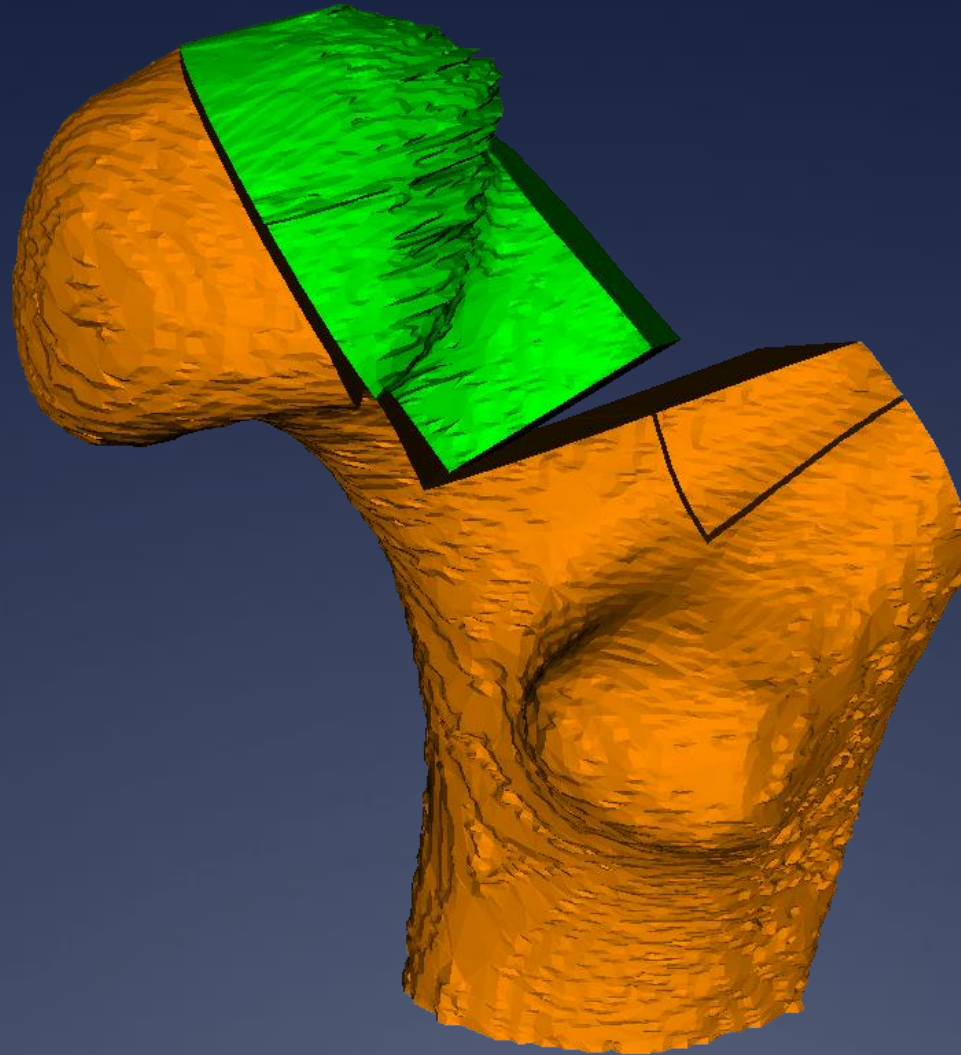
Simulated Postop



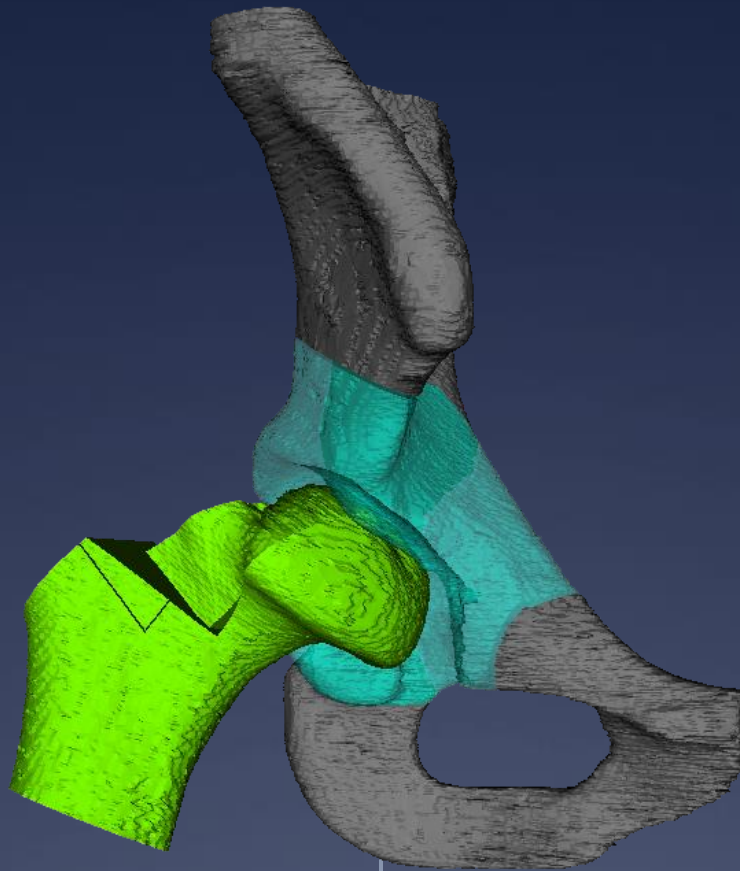


# Simulated Postop

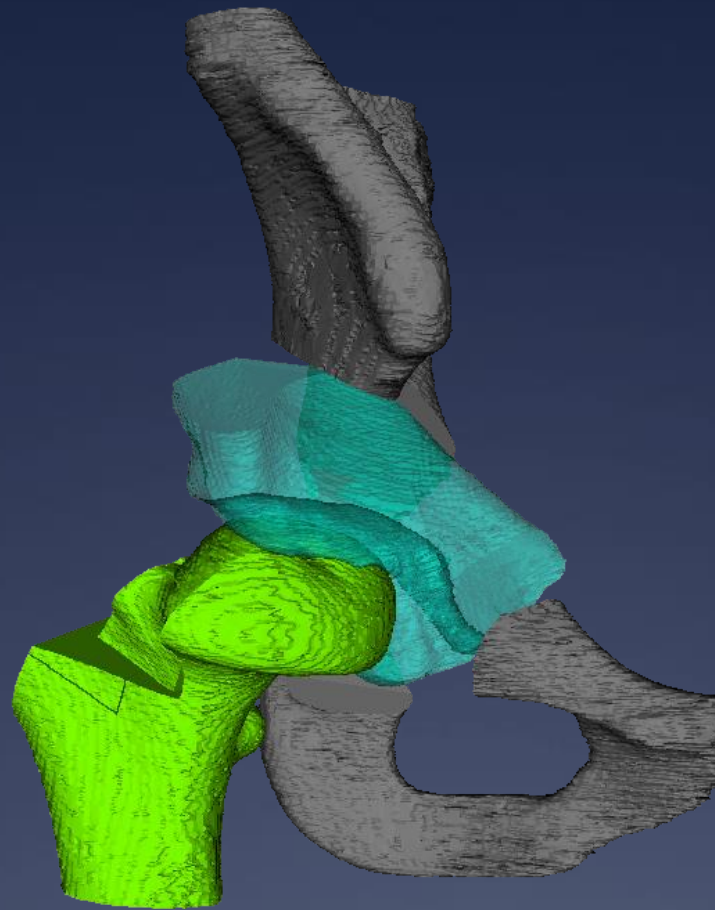
27.09.2025



Simulated Postop

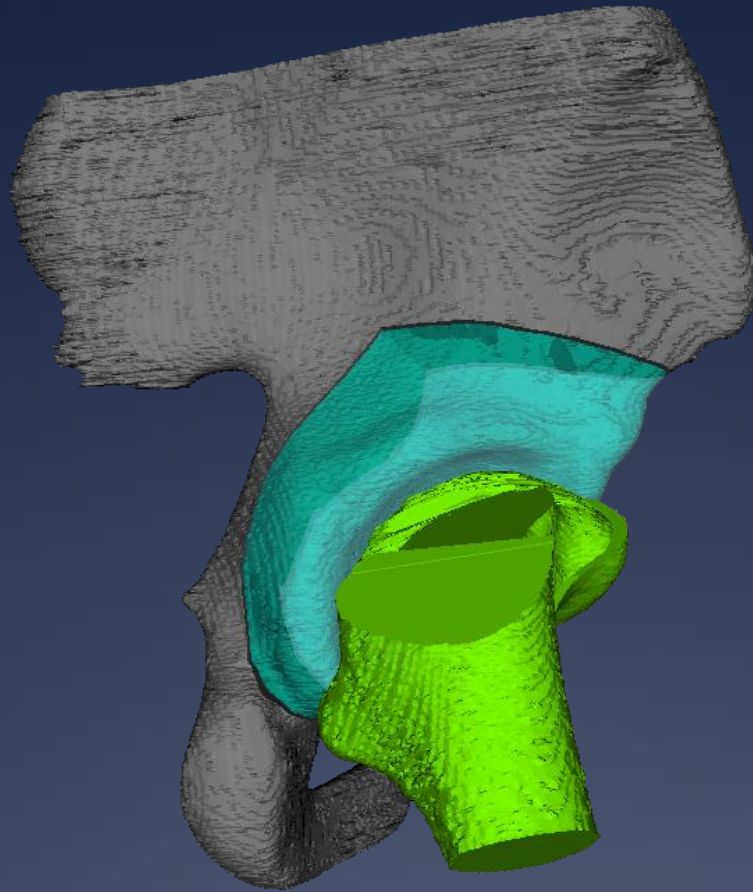


Simulated Postop before PAO

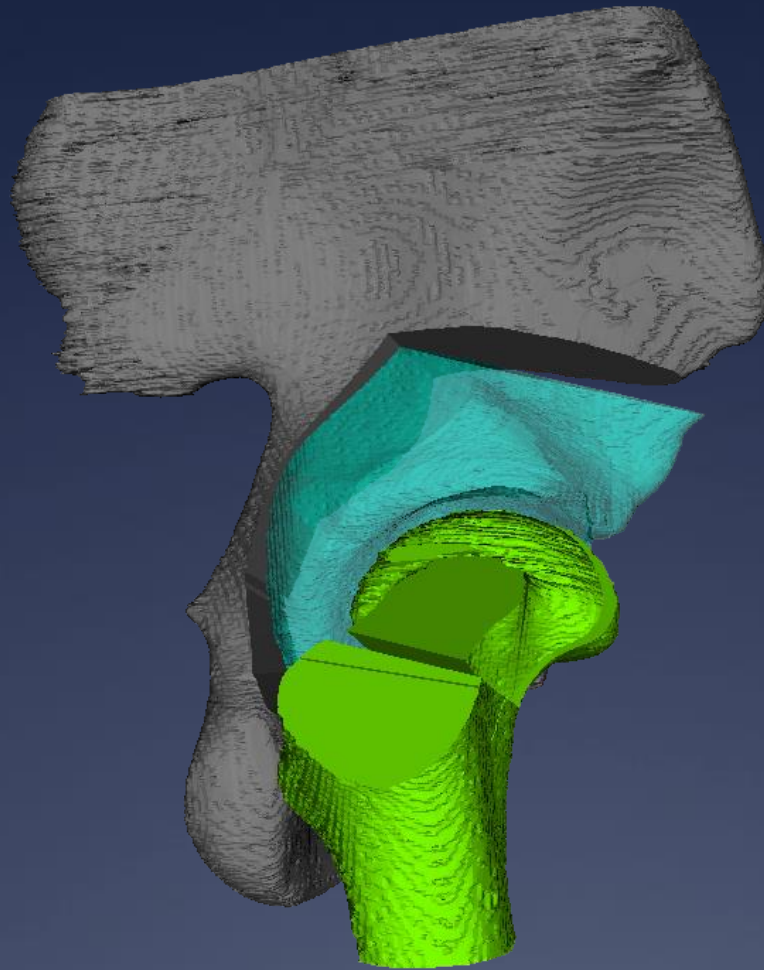


Simulated Postop after PAO





Simulated Postop before PBO



Simulated Postop after PAO

# Thank You

