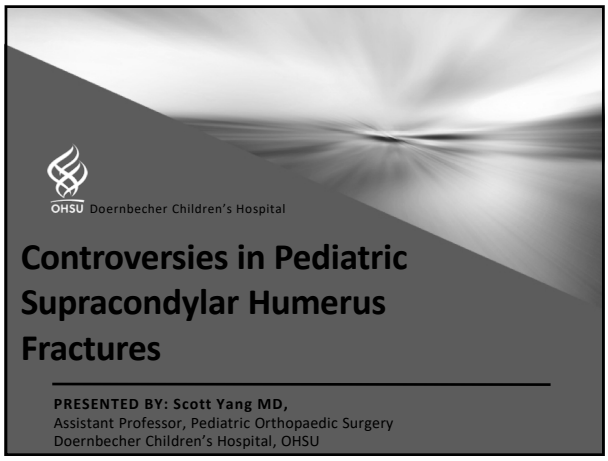

No disclosures for this presentation

2

Doernbecher Children's Hospital

Agenda

- A **basic** review of supracondylar humerus fracture
  - Anatomy
  - Classification
  - Treatment
- A Biased and Personal Take on Controversies
  - Type II – to cast or pin?
  - Timing of treatment – immediate or delayed?
  - Vascular Injury – The pink pulseless hand

Image credits:
1) AO Surgery Reference

3

Doernbecher Children's Hospital

Background

- Supracondylar humerus fractures are one of the most common types of fractures in children
  - 60% of all elbow trauma in children
- Extension type most common (95%)
- Risk of neurovascular injury, compartment syndrome

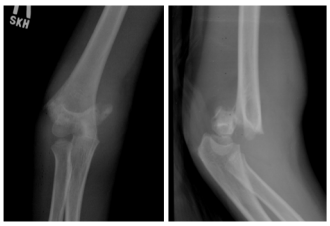

Doernbecher Children's Hospital

4

Supracondylar Humerus Fractures Classification

- Type 1
  - Non-displaced
- Type 2
  - Angulated/displaced fracture with intact posterior cortex
- Type 3
  - Complete displacement, with no contact between fragments
- Type 4 (new)
  - Instability in flexion and extension intraoperative

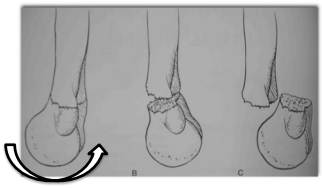

I II III

Doernbecher Children's Hospital

Elbow Fractures Radiograph Anatomy/Landmarks

- Anterior Humeral Line
  - Drawn along the anterior humeral cortex
  - Should pass through the middle of the capitellum
    - >5 y/o, 100% falls on middle 1/3
  - Variable in very young children
    - < 2 y/o, 30% fall on anterior 1/3

Credit:
-Rogers et al, Radiology 1998
-Herman, et al JBJS 2009
-Ryan et al, JPO 2016

Doernbecher Children's Hospital

Importance of True Lateral Xray

- Indistinct capitellum
- Malrotated image

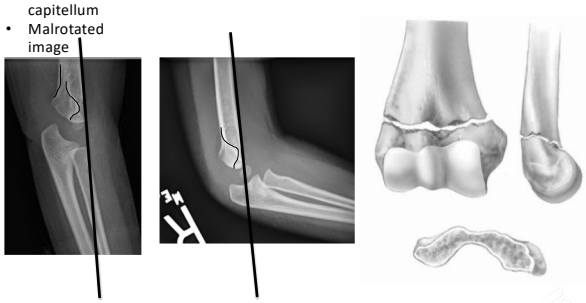

Doernbecher Children's Hospital

Radiograph Measurements

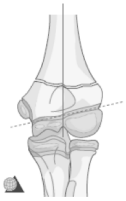

- Baumann's angle
  - Shaft-capitellar angle (>75° = varus)
    - Wide range of normal
- ← Medial impaction and varus position increases Bauman's angle

Image Credits:
1) Mohammad et al JPO 2009
2) AO Surgery Reference

Doernbecher Children's Hospital

Type 1
Non-displaced

- Look for fat pad
  - Posterior fat pad elevation, 76% have occult fracture
- Treat with cast immobilization for 3 weeks

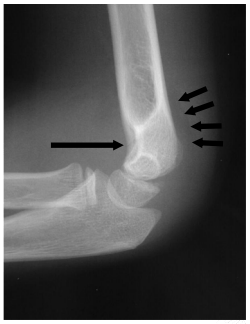

Credit
-Skaggs DL et al, JBJS 1999
-Bohrer et al, Clin Radiol. 1970;21:90.

Doernbecher Children's Hospital

Type 2

Angulated/displaced fracture with intact posterior cortex

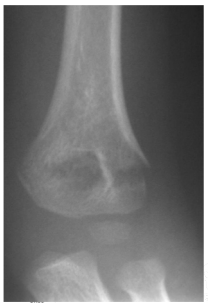

Caution - Type 2 – Coronal plane is important too

Type II fracture with medial impaction – not recognized and varus / extension not reduced

Doernbecher Children's Hospital

Type 2 Treatment Goals

- Restoration of alignment in the lateral view (anterior humeral line intersect capitellum)
- Restoration of bauman's angle and clinical carrying angle
- Hold the reduction

Doernbecher Children's Hospital

Type 2 - Treatment

- Closed reduction & casting
  - vs
- Closed reduction & percutaneous pinning

Controversy #1

Do all type II supracondylar humerus fractures need pins?

Doernbecher Children's Hospital

Casting can work in select patients…

Spencer et al, JPO 2012

- 189 type II fractures treated with closed reduction & casting
  - 79% maintained reduction
  - Loss of reduction associated with:
    - Rotation
    - Persistent extension post-reduction
- Bottom line:
  - **Some** type II's can be treated with casting

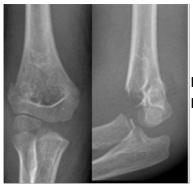

Rotational Malalignment

TABLE 8. Multivariate Logistic Regression Analysis for Subsequent Conversion to Surgical Treatment Among the 189 Patients Who Did Not Receive Initial Surgical Treatment

Radiographic Features	n	Odds Ratio	SE	95% Confidence Interval	P
Initial rotational deformity	6	17.8	20.47	1.85-170.0	0.013
Postreduction anterior humeral line remaining anterior to the middle third of the capitellum	67	3.96	1.60	1.80-8.74	0.001

Area under the receiver-operating characteristic curve using these 2 variables alone was 0.6985 (lower discrimination).

Proponents of Operative Treatment

- Principles
  - Decreased loss of reduction
  - Decreased radiographic follow up
  - Low complication rate from pinning
- Douglas et al, JOT 2013
  - 29 type II SCHs → closed reduction and casting
    - **48% lost reduction,** > 5 degrees (mean 12 degrees)
    - Position of casting & initial displacement didn't matter
- Skaggs et al, JPO 2008
  - 189 type II SCHs → CRPP
    - **0% loss of reduction,** clinical varus, or ROM loss (6 weeks post pin-removal)
    - 2.1% pin site infection rate (4/189)

Doernbecher Children's Hospital

Proposed Algorithm

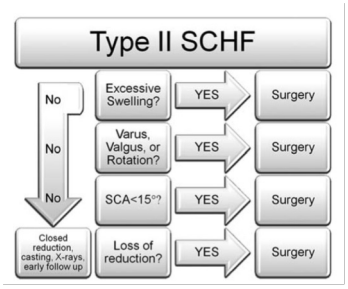

Credit
-Spenser et al, JPO 2012

Doernbecher Children's Hospital

Conclusion

- Personal preference –
  - Too much to think about

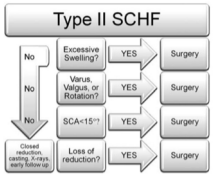

  - **Pin all type 2 supracondylar humerus fractures**
    - Prevents need for repeated radiographic follow ups
    - Minimizes loss of reduction and extension/varus deformity
    - Pin complication rate acceptable

Doernbecher Children's Hospital

Type 3
Complete displacement, with no contact between fragments

- Higher risk of neurologic and/or vascular compromise
  - 10-20% (Omid et al, JBJS 2008)
- Risk of compartment syndrome
- Treat with closed reduction & percutaneous pinning
  - Rarely, open reduction

Doernbecher Children's Hospital

Type 3 - Neurovascular Anatomy

- Median / AIN injury 59% of all nerve injuries
- Artery close proximity to median nerve
- Brachial artery draped across proximal fragment
  - Tethered by supratrochlear artery
- Urgency of CRPP depends on vascular status / compartment syndrome risk

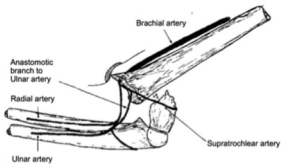

Image Credits:
1) Rowell PJ, Injury 1975
2) Aksakal et al, Acta Orthop Traumato Turc 2013

Type 3, Caution

- Important to *assess* and *document* **preoperative** status on nerve function & vascular status!!
  - Cases of median nerve and brachial artery entrapment at fracture site s/p reduction (Marshall et al, BMJ Case Rep 2015; Thorleifsson et al, AOTS 1988)

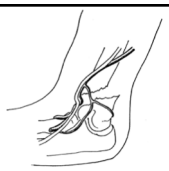

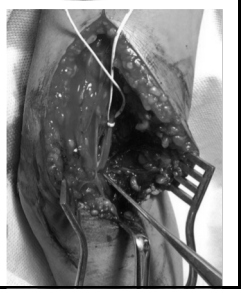

Type 3 Initial Presentation

- Pulse absent, poorly perfused hand
  - **EMERGENT** reduction / pinning
- Pulse absent, well perfused hand
  - **URGENT** reduction / pinning
- Pulse present, well perfused hand
  - **How long can these wait for** reduction/pinning

Doernbecher Children's Hospital

A quick word about Pulseless Poorly Perfused Hand On Presentation

Choi et al, JPO 2010
- Pulseless SCH w/ white hand
- → observe CLOSELY postop for deterioration

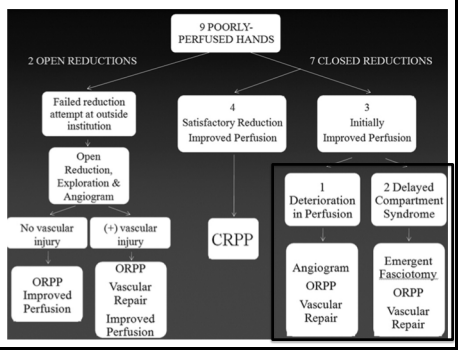

Controversy #2

- Do type III supracondylar humerus fractures with intact pulse and perfused hand need urgent surgical treatment?

Doernbecher Children's Hospital

Proponents of early treatment

Louizou et al, Injury 2008

- Meta-analysis favored early treatment (<8-12 hrs from presentation)
  - Delaying treatment associated with increased risk of open reduction

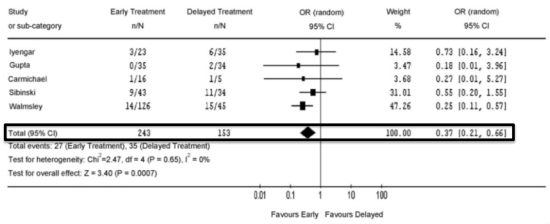

Louizou et al, 2008

Doernbecher Children's Hospital

A Closer Look at the Largest Study

Walmsley et al, JBJS UK 2006

- < 8 hr, 11% open reduction
- > 8 hr, 33.3% open reduction
- Outlier
  - ~ < 15 % open reduction rate in other studies

Table II. Number of complications

	A	B	p value
Closed (%)	112 (*88.8*)	30 (*66.6*)	< 0.05
Open (%)	14 (*11.2*)	15 (*33.3*)	< 0.05
Median nerve palsy (%)	13 (*10.3*)	6 (*13.3*)	NS*
Ulnar nerve palsy (%)	4 (*3.1*)	1 (*2.2*)	NS
Radial nerve palsy (%)	5 (*3.9*)	2 (*4.4*)	NS
Anterior interosseous palsy (%)	10 (*7.9*)	4 (*8.8*)	NS
Wound infection	1	1	-
Cubitus varus	5	3	-

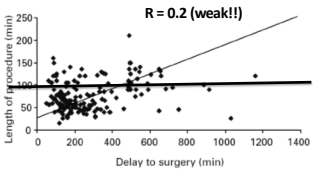

Proponents of Delayed Treatment

Study	Timing Groups (Mean)	% open reduction	Other Complications/ROM/Radiographs
Kronner et al (JCO 2013)	Early < 12 hrs (7.4) Late > 12 hrs (16)	Early : 7.4% Late : 13.2% P = 0.37	No difference
Gupta et al (JPO 2004)	Early < 12 hrs Late > 12 hrs	Early: 0% Late: 6% P = 0.24	No difference
Leet at al (JPO 2002)	Spectrum (correlation analysis – no correlation)	Overall: 0.6%	No difference
Lyengar et al (JOT 1999)	Early < 8 hr (5.3) Late > 8 hr (22.1)	Early: 13% Late: 17% P = 0.47	No difference

- No difference in rate of open reduction
- No difference in quality of reduction
- No difference in eventual functional outcomes

Doernbecher Children's Hospital

Delaying treatment of supracondylar fractures in children

HAS THE PENDULUM SWUNG TOO FAR?

Ramachandran et al, JBJS UK 2008

- What can we learn from patients who got compartment syndrome?
  - 11 patients with **type III SCHs w/ intact pulse** on presentation who developed compartment syndrome
  - Mean time from injury to surgery 22 hours
  - On presentation warning signs
    - Severe swelling in 10/11
    - Puckering in 2/11
    - Ecchymosis in 7/11
- Use clinical judgment – **take warning signs into account**

Doernbecher Children's Hospital

Conclusion

- Personal bottom line
  - In well perfused, intact pulse case without other risk (severe swelling, ecchymosis, puckering) factors, OK to wait until next morning
    - **Would you want your child waiting with severe swelling/ecchymosis/puckering?**
  - Still attempt to perform CRPP **as soon as reasonably possible**

Doernbecher Children's Hospital

Surgical Treatment of Supracondylar Humerus Fractures

- Positioning
  - Radiolucent small hand table
    - OK to use fluoroscopy as table
  - Axilla at the edge of bed

Image credit:
Skaggs et al, Masters Techniques in Orthopaedic Surgery, Pediatrics, 2015

Doernbecher Children's Hospital

Surgical Treatment of Supracondylar Humerus Fractures

- Step 1:
  - Milk Brachialis,
    - get tethered soft tissues out of way to reduce risk of neurovascular entrapment

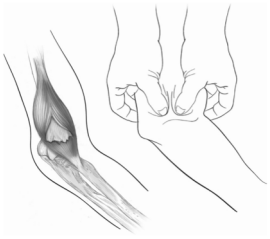

Image credit:
Skaggs et al, Masters Techniques in Orthopaedic Surgery, Pediatrics, 2015

Doernbecher Children's Hospital

Surgical Treatment of Supracondylar Humerus Fractures

- Step 2:
  - Traction
  - Reduce in coronal plane
  - Check fluoroscopy

Image credit:
Skaggs et al, Masters Techniques in Orthopaedic Surgery,: Pediatrics, 2015
Flynn et al, Lovell and Winters Pediatric Orthopaedics, 2014

Doernbecher Children's Hospital

Surgical Treatment of Supracondylar Humerus Fractures

- Step 3:
  - Correct rotation
  - Flexion maneuver w/ direct thumb pressure on distal fragment
    - Don't be overly aggressive (iatrogenic type IV)

Image credit:
Skaggs et al, Masters Techniques in Orthopaedic Surgery, Pediatrics, 2015

Doernbecher Children's Hospital

Surgical Treatment of Supracondylar Humerus Fractures

- Step 4
  - Check transcondylar view
  - Verify reduction on lateral view
    - External rotation @ shoulder
    - Move the humerus!

Image credit:
Skaggs et al, Masters Techniques in Orthopaedic Surgery, Pediatrics, 2015

Doernbecher Children's Hospital

Surgical Treatment of Supracondylar Humerus Fractures

- Step 5 –
  - Place percutaneous pins in the transcondylar view
  - Maximize divergence of the pins

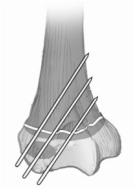

Image credit:
Skaggs et al, Masters Techniques in Orthopaedic Surgery, Pediatrics, 2015

Surgical Treatment of Supracondylar Humerus Fractures

- Personal preferred technique:
  - Lateral only pins
    - Two lateral pins for type II
    - Three lateral pins for type III

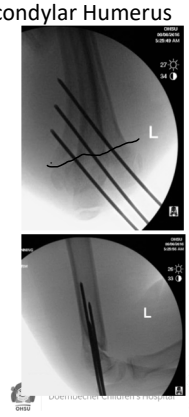

Surgical Treatment of Supracondylar Humerus Fractures

- Step 7
  - Check pulse!
  - Do not leave OR until hand is well perfused

Doernbecher Children's Hospital

Scenarios after successful closed reduction & pinning



Scenarios AFTER CRPP, with 2012 AAOS Guidelines

1) Intact pulse → done

2) Absent pulse, well perfused

Pulseless and perfused hand after reduction/pinning → Open exploration vs observation?.
- Strength of Recommendation: **Inconclusive**

3) Absent pulse, poorly perfused

Pulseless and decreased perfusion to hand after reduction/ pinning → Open exploration of the antecubital fossa
- Strength of Recommendation: **Consensus**

Doernbecher Children's Hospital

Pulseless but perfused after reduction: Observe?

Weller et al, JBJS 2013

- 54 pulseless type III supracondylar humerus fractures
- All underwent reduction & pinning

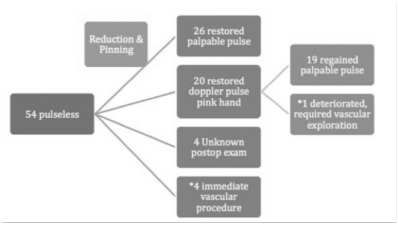

Doernbecher Children's Hospital

Pulseless but perfused after reduction: Observe?

TABLE I Patients Requiring Vascular Surgery

	Postreduction Examination	Surgical Finding and/or Intervention
Patient 1	Pink hand, no pulse detected with use of Doppler ultrasound	Intimal tear resected with primary repair; angiogram done
Patient 2	Brisk capillary refill, no pulse detected with use of Doppler ultrasound	Patch angioplasty with saphenous graft
Patient 3	Sluggish capillary refill; no pulse detected with use of Doppler ultrasound	Thrombosed brachial artery; saphenous graft repair (interpositional)
Patient 4	Open fracture (Gustilo and Anderson grade II*); pink hand, no pulse detected with Doppler ultrasound	Brachial artery laceration with primary repair
Patient 5	Brisk capillary refill and normal ("triphasic") Doppler velocity waveform initially; cool, pale hand 9 hrs postoperatively	Thrombosed brachial artery; saphenous graft bypass (9 hrs after reduction)

- SAFE : Pink, but dopplerable pulse afterwards - observe patients **24-48 hours**
- UNCLEAR: Role of Doppler signal in pink perfused hand
  - Everyone without doppler signal had true brachial artery finding

Doernbecher Children's Hospital

Pulseless but perfused after reduction: How do they do?

Scanell et al, JBJS 2013

- 20 patients s/p CRPP for pulseless perfused SCH fx
  - Mean 20 months f/u
- Outcomes:
  - 7/20 (35%) – Early palpable pulse after reduction
  - **20/20 (100%) – Palpable pulse at final follow up**
  - Duplex scan:
    - 14 patent brachial artery
    - 5 occlusion / 1 stenosis of brachial artery
  - Clinical exam:
    - No difference in circumference, length, ROM, grip strength, muscle endurance compared to uninjured side
    - **3 osteonecrosis of trochlea, 1 distal humeral chondrolysis**

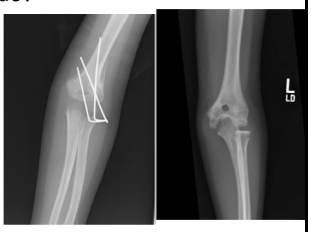

1) Collateral flow around elbow allows for palpable pulse
2) Observed pink pulseless do OK clinically in medium term
3) Need longer term follow up!

Doernbecher Children's Hospital

- Prevent ischemic contracture long term
- Blakey et al JBJS UK 2009
  - 26 patients referred after treatment of pulseless perfused SCH fx
  - 23/26 patients had evidence of ischemic contracture upon referral

Doernbecher Children's Hospital

Pink Pulseless Hand – Other helpful tests?

- Bae et al: "We recommend surgical exploration in patients with pink pulseless hand if there is *any* evidence of altered perfusion (after CRPP) – ischemic pain, sluggish capillary refill, abnormal doppler signal)
- Adjuncts
  - Doppler for pulse
  - Pulse oximetry waveform?

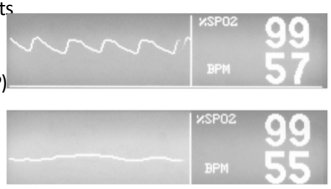

Image credit:
Soh et al, CIOS 2013

Doernbecher Children's Hospital

Conclusion

- Observe pink pulseless hand 24-48 hours, with serial checks for compartment syndrome and vascular compromise
  - Be weary of nerve injury that mask a good examination
- Use best judgment to assess adequacy of perfusion
  - Doppler? Pulse Ox?
- Be Ready to Intervene!
- Still need longer f/u and more objective ways to assess adequacy of perfusion

Doernbecher Children's Hospital

Thank You

Doernbecher Children's Hospital