SURGICAL CONSIDERATIONS IN THE CARE OF THE COMBAT AMPUTEE

Wade Gordon, MD – Col (Former), USAF MC
Orthopaedc Trauma Surgeon
Southern Oregon Orthopedics
Medford, OR
Associate Professor, Uniformed Services University of the Health Sciences

Prologue: Amputation Surgery

- "War is the only proper school for surgeons"
  - Hippocrates
- Difficult to discuss surgical aspects of amputee care without photographs

"War makes a better human being out of you because you are exposed to war's inhumanity, so the value of humanity becomes very dear. War is an obscene laboratory experience, but perhaps it has to be. If we don't gain something positive from the horrible negatives of war, we've not done our duty. What we as doctors should come away with is better care of the wounded, greater survival, and less disabilities. That seems to be where we should be headed, but the real goal is just to get rid of all wars."

John T Hayes, MD

"War makes a better human being out of you because you are exposed to war's inhumanity, so the value of humanity becomes very dear. War is an obscene laboratory experience, but perhaps it has to be. If we don't gain something positive from the horrible negatives of war, we've not done our duty. What we as doctors should come away with is better care of the wounded, greater survival, and less disabilities. That seems to be where we should be headed, but the real goal is just to get rid of all wars."

John T Hayes, MD

Amputee Care!!!!

Overview

- General Principles of Traumatic Amputations
  - Decision Making
  - Tissue Management
  - Amputation Levels and Techniques
- Issues Specific to the Combat Amputee
  - Patient Population
  - Blast Injury
  - Complications
- Clinical Cases

Overview – General Principles

- General Principles of Traumatic Amputations
  - Amputate or Not?
  - Wound and Soft Tissue Management
  - Preservation of Length
  - Functional Levels – Upper and Lower Extremities
  - Basic Techniques
  - Late Amputations

What Does This Have to Do With Me?

71 yo Male - MCA

Amputation vs Limb Salvage

- Sometimes – Made For You
- Other Times – Really Difficult Decision
- Limb Salvage
  - "Reconstructing a limb that MAY have a better functional outcome with amputation"
- Poor Candidates for Both
  - Often attempt limb salvage

Amputation vs Limb Salvage

- Sometimes – Made For You
- Other Times – Really Difficult Decision
- Limb Salvage
  - "Reconstructing a limb that MAY have a better functional outcome with amputation"
- Poor Candidates for Both
  - Often attempt limb salvage

Amputation vs Limb Salvage

- Sometimes – Made For You
- Other Times – Really Difficult
- Limb Salvage
  - "Reconstructing a limb that MAY have a better functional outcome with amputation"
- Poor Candidates for Both
  - Often attempt limb salvage

Poor Candidates for Both

Initial course of limb Salvage

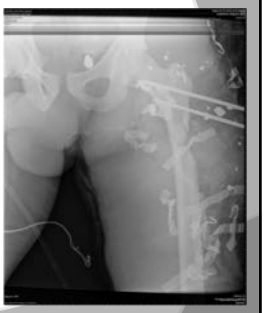

Indications for Amputation

- Absolute
  - Inability to obtain:
    - Perfused limb
    - Mechanical stability
  - Unreconstructible Soft Tissue Envelope
- Relative
  - Failed Attempt at Limb Salvage
  - Sound contralateral limb
  - Expectation of poor ultimate function
- Absent Plantar Sensation??

Indications for Amputation

- Absolute
  - Inability to obtain:
    - Perfused limb
    - Mechanical stability
  - Unreconstructible Soft Tissue Envelope
- Relative
  - Failed Attempt at Limb Salvage
  - Sound contralateral limb
  - Expectation of poor ultimate function
- Absent Plantar Sensation??

NO!!

Goals in Amputation Surgery

- Basic Tenets
  - Preserve Length – functional levels
  - Preserve Viable Soft Tissue
  - Soft Tissue Coverage & Closure
- Provide Optimal Function
- Different Goals
  - Upper Extremity: Length at cost of tissue coverage
  - Lower Extremity: Soft tissue padding important

Management of Tissues

- Open Wounds – Zone of Injury
- Muscle
- Bone
- Vessels
- Nerves
- Skin
  - Timing of Closure of Amputations
  - Atypical Skin Flaps

Open Wounds

- Serial debridements
- Remove foreign contamination & necrotic tissue
- Preserve viable:
  - Muscle
  - Skin
- Obtain healthy/clean soft tissue envelope

Tissue Management: Muscle

- Provides Padding for Weight Bearing
- Function and Mechanical Stability
  - Myodesis
  - Myoplasty
- Appropriate Tension Critical for Optimal Function

Tissue Management: Muscle

- Provides Padding for Weight Bearing
- Function and Mechanical Stability
  - Myodesis
  - Myoplasty
- Appropriate Tension Critical for Optimal Function

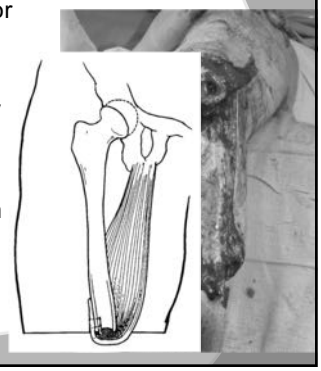

Tissue Management: Bone

- Usually not the determinant of functional level
- Keep at most distal viable level of soft tissues
- Fractures?

Fractures in Amputated Limbs

- Treat fractures proximal to the most distal viable level as you would an isolated injury
  - 37 Combat amputees with fixation of proximal fractures
  - 32% with fracture fixed in same osseous segment
  - Mean Tegner score 3.3: Acceptable functional outcome
  - High rates of infection (89%) and HO (72%)

Outcomes Associated With the Internal Fixation of Long Bone Fractures Proximal to Ipsilateral Traumatic Amputations. Gordon WT, O'Brien FP, Strauss JE, Andersen RC, Potter BK. Pending Publication

Tissue Management

- Vessels
  - Ligated proximal to level of bone
  - Arteries and veins ligated separately
- Nerve – PREVENT NEUROMAS
  - Transect all major nerves
  - Dissected free
  - Drawn into wound
  - Sharply transected
  - Retract into muscle tissue

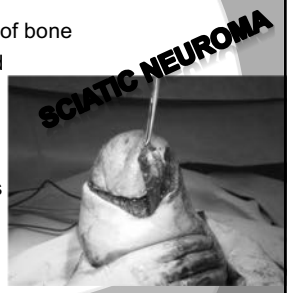

Tissue Management: Skin

- Often determines amputation level
- Avoid skin grafting to residual limb
- Preserve all viable skin flaps
- Atypical skin flaps
  - Creative use of intact, native skin

Atypical Skin Flaps

Atypical Skin Flaps

Atypical Skin Flaps

Timing of Closure

- Wounds kept open until deemed ready
- HOW DO YOU KNOW??

Timing of Closure

- Wounds kept open until deemed ready
- HOW DO YOU KNOW??
  - Cultures?
  - Wound clean on inspection at debridement?

Timing of Closure

- Wounds kept open until deemed ready
- HOW DO YOU KNOW??
  - Cultures?
  - Wound clean on inspection at debridement?
- Now: Subjective assessment

Timing of Closure

- Wounds kept open until deemed ready
- HOW DO YOU KNOW??
  - Cultures?
  - Wound clean on inspection at debridement?
- Now: Subjective assessment
- Future: Cytokine panel to predict wound readiness for closure
  - Analysis of wound effluent

Inflammatory biomarkers in combat wound healing. Hawksworth JS, Stojadinovic A, Gage FA, Tadaki DK, Perdue PW, Forsberg J,Davis TA, Dunne JR, Denobile JW, Brown TS, Elster EA. Ann Surg. 2009 Dec;250(6):1002-7.

Overview

- General Principles of Traumatic Amputations
  - Decision Making
  - Tissue Management
  - Amputation Levels and Techniques
- Issues Specific to the Combat Amputee
  - Patient Population
  - Blast Injury
  - Complications
- Clinical Cases

Amputation Levels

- Lower Extremity
  - Partial Foot
  - Syme
  - Transtibial
  - Knee Disarticulation
  - Transfemoral
  - Hip Disarticulation
- Increased Function vs. Decreased Complications

Transtibial Amputations

- 85% of Amputations
- Length Determination
  - Ideal: 12.5 cm to 17.5 cm
    - 2.5 cm of bone length for each 30 cm of body height
- Short Below the Knee Amputation

Transtibial Amputations

- Posterior skin flaps
- Gastrocnemius/Soleus myodesis
  - Bone coverage/padding
- 5 Nerves
- 3 Arteries
- Skin closure without tension
- Limb Shaping

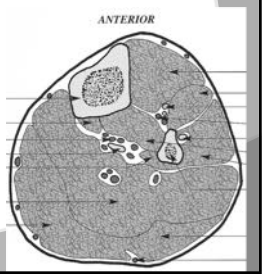

Ertl Procedure

- Osseous bridge between tibia and fibula
- Stabilized with screws or suture
  - Tightrope
- May provide better function with high-end activities
- Typically not used in open traumatic amputations

Ertl Procedure

- Osseous bridge between tibia and fibula
- Stabilized with screws or suture
  - Tightrope
- May provide better function with high-end activities
- Typically not used in open traumatic amputations

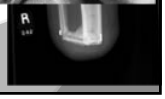

Thigh (Transfemoral) Amputation

- Second Most Common Amputation Level
- Ideal Length: 9-14.5 cm proximal to Knee
- Short Residual Limbs: < 5 cm

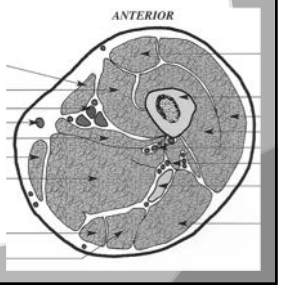

Transfemoral Amputations

- Posterior Skin Flaps
  - Variable
- Muscle Attachments Critical to Function
  - Adductor/Hamstring myodesis
  - Quadriceps myoplasty
- Nerves
- Vessels

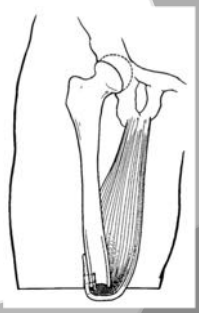

Transfemoral Amputations

- Posterior Skin Flaps
  - Variable
- Muscle Attachments Critical to Function
  - Adductor/Hamstring myodesis
  - Quadriceps myoplasty
- Nerves
- Vessels

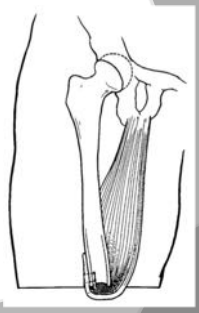

Snapping Myodesis

Myodesis Failure

- Vascular clip as monitoring device

Amputation Levels

- Upper Extremity 1:4 ratio compared to lower
  - Partial Hand/Fingers
  - Wrist Disarticulation
  - Transradial*
  - Elbow Disarticulation
  - Transhumeral*
- *Length Preservation Extremely Important

Preservation of Length

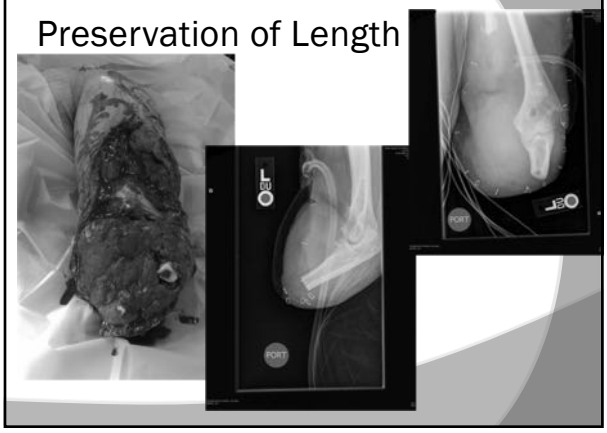

Preservation of Length

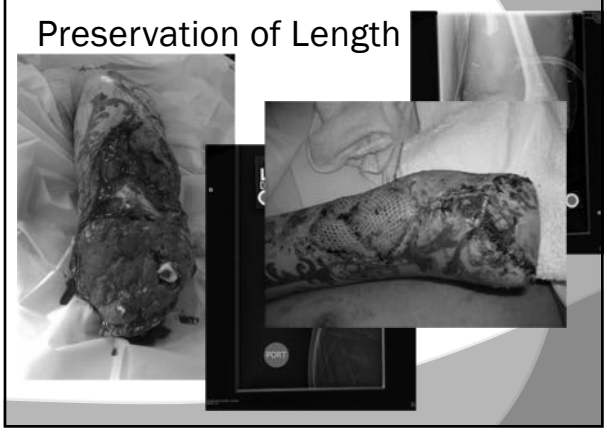

Delayed Amputations

- Not All Combat Related Amputations Are Performed Acutely
- Failed Limb Salvage
  - Pain
  - Poor Joint Mobility
  - Poor Function
- ERTL – Unknown benefit

Overview

- General Principles of Traumatic Amputations
  - Decision Making
  - Tissue Management
  - Amputation Levels and Techniques
- Issues Specific to the Combat Amputee
  - Patient Population
  - Blast Injury
  - Complications
- Clinical Cases

Combat Specific Amputation Surgery

- Patient Population
- Technical Considerations
  - Zone of Injury
  - Often Bad Amputation candidates
- Complications
  - Heterotopic Ossification
  - Infection
- Unusual Amputations
  - "Turn-up plasty"
  - Atypical Skin Flaps

Combat Related Amputations

- Patient Population – Young, motivated, highly functional patients
- Access to best available rehab/prosthetic care

Combat Specific Amputation Surgery

- Patient Population
- Technical Considerations
  - Zone of Injury
  - Often Bad Amputation candidates
- Complications
  - Heterotopic Ossification
  - Infection
- Unusual Amputations
  - "Turn-up plasty"
  - Atypical Skin Flaps

Combat Amputations – Special Technical Considerations

- Working in Zone of Injury
  - Preserving Length
  - Zone of Injury Extensive
  - Increased Function vs Increased Infection
  - Increased Risk of Heterotopic Ossification
- Extensive Soft Tissue/Skin Injury
  - Challenging/Atypical Closure
  - Poor Amputation and Salvage Candidates

Combat Specific Amputation Surgery

- Patient Population
- Technical Considerations
  - Zone of Injury
  - Often Bad Amputation candidates
- Complications
  - Heterotopic Ossification
  - Infection
- Unusual Amputations
  - "Turn-up plasty"
  - Atypical Skin Flaps

This Leads to a Specific Set of Complications

- Heterotopic Ossification
- Infection
- Skin Flap Necrosis/Breakdown

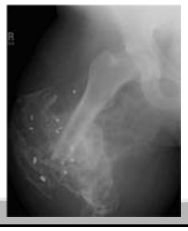

Heterotopic Ossification

- What Is It?
  - Formation of bone in other tissues
  - Damaged muscle
- Approximately 66% of Combat Amputation Patients
- Approximately 40% of those require surgery

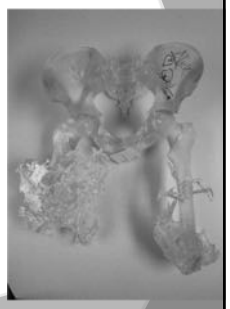

Heterotopic Ossification

- Approximately 66% of Combat-Related Amputations

Associated with:

Pain
Extended Recovery Time
Poor Prosthetic Fitting
Revision Surgeries
Breakdown of Soft Tissues
Damage to Nerves and Vessels
Nursing: pt's complain of hard mass

- Prevention: Focused Radiation Therapy or NSAIDS

54/5

Infections

- Combat – contaminated environment
- Amputations in Zone of Injury
- Extensive Open Wounds
- Infection Rate – 20 – 40% in various series
  - 89% in amputations with fixed fractures

Infection - Treatment

- Debridement of Infected Tissue
  - Skin
  - Muscle
  - Shortening Bone
- Local and Systemic Antibiotics
- Maintain Fracture Implants
- Delayed Primary Closure
- Rarely Lose a Functional Level

Overview

- General Principles of Traumatic Amputations
  - Decision Making
  - Tissue Management
  - Amputation Levels and Techniques
- Issues Specific to the Combat Amputee
  - Patient Population
  - Blast Injury
  - Complications
- Clinical Cases

Clinical Case #1

- 22 year old male – IED blast with multiple injuries

•Right comminuted tibia/fibula fxs with nerve injury
•Left transtibial amputation
•Abdominal, ocular and head injuries

•Intramedullary nail and bone grafting
•Deep infection
•Conversion to circular external fixator
•Repeat bone grafting

•Ultimately failed limb salvage with segmental bone defect

Clinical Case 1

- Turn-up Plasty

Clinical Case #1 – Turn-up Plasty

Clinical Case #2

- 24 year old – IED blast - severe right foot injury, segmental tibia fracture, and femoral shaft fracture

•Intramedullary nail fixation of femur
•Transtibial amputation at standard length
•Open reduction and internal fixation of proximal tibia fracture

Clinical Case #2

- Amputation with Proximal Fracture Fixation

•Intramedullary nail fixation of femur fracture

•Transtibial amputation

Clinical Case 2

- Amputation with Proximal Fracture Fixation

Questions

THANK YOU